NINDS Common Data Element (CDE) Project
Stroke Version 2.0 Public Review
Imaging Subgroup Materials

Summary Document:

- Imaging Subgroup Summary

Case Report Forms:

- Aneurysm Location and Dimensions
- Cardiac Magnetic Resonance Imaging
- Echocardiogram
- Echocardiogram II
- Imaging Acquisition
- Parenchymal Imaging
- Perfusion and Penumbral Imaging
- Vessel Carotid Ultrasound
- Vessel Imaging Angiography
- Vessel Imaging Transcranial

Stroke Version 2.0 NINDS CDE Project

Name of Stroke v2.0 Subgroup: Imaging
Completed by: David S Liebeskind, MD
Date: January 15, 2020

Please answer the following questions below.

1. **Approach for selection of elements** (*How did you go about drafting the recommendations and/or reviewing the current tools/instruments, and did you have any criteria for selection and classification?)*
   Revision of prior documents, review of interval scientific literature relating to use of specific metrics or elements, broad inclusion of data elements, panel discussions on each topic, hierarchical use or prioritization of data elements, final review of all stroke imaging CDE.

2. **Differential application to types of Stroke** *(Do the instruments/elements you recommended differ between the types of Stroke?)*
   Yes, specific applications and uses in distinct subtypes have been noted.

3. **Differential application to adult and pediatric and other subpopulations within Stroke patients** *(Do the instruments/elements you recommended differ between target populations within Stroke?)*
   No

4. **Summary of recommendations**

Instrument / Scale / CRF Name	Domain	Subdomain	Classification
Aneurysm Location and Dimensions CRF	Assessments and Examinations	Imaging Diagnostics	**Exploratory:** Digital Subtraction Angiography (DSA) site of access anatomic site; Intracranial stenosis present indicator; Contralateral steno-occlusive vessel disease indicator; Aneurysm follow-up shape type **Supplemental:** All other CDEs
Cardiac Magnetic Resonance Imaging CRF	Assessments and Examinations	Imaging Diagnostics	**Supplemental:** All CDEs
Echocardiogram CRF	Assessments and Examinations	Imaging Diagnostics	**Supplemental:** All CDEs
Echocardiogram II CRF	Assessments and Examinations	Imaging Diagnostics	**Supplemental:** All CDEs
Imaging Acquisition CRF	Assessments and Examinations	Imaging Diagnostics	**Supplemental:** All CDEs
Parenchymal Imaging CRF	Assessments and Examinations	Imaging Diagnostics	**Exploratory:** Imaging one third middle cerebral artery territory involved indicator **Supplemental:** All other CDEs

Perfusion and Penumbral Imaging CRF	Assessments and Examinations	Imaging Diagnostics	[CDEs to be classified]
Vessel Carotid Ultrasound CRF	Assessments and Examinations	Imaging Diagnostics	**Supplemental-Highly Recommended:** Imaging study ID number; Imaging study date and time; Imaging B-mode finding result; Imaging echo pattern result; Imaging plaque surface type; Imaging plaque severity grade; Imaging color flow angle measurement; Imaging peak velocity measurement; Imaging end diastolic velocity measurement; Imaging signal indicator; Imaging percent stenosis criterion type; Imaging stenosis percentage value **Supplemental:** All other CDEs
Vessel Imaging Angiography CRF	Assessments and Examinations	Imaging Diagnostics	**Supplemental-Highly Recommended:** Imaging study ID number; Imaging study date and time; Imaging modality vessel imaging angiography type **Exploratory:** Qureshi angiographic occlusions scale score; Imaging aneurysm 3D reconstruct indicator; Wall opposition stent flow diverter quality grade; Imaging aneurysm occlusion percent value; Imaging aneurysm kinetic energy mean measurement; Imaging mean blood velocity measurement; Imaging aneurysm shear rate mean measurement; Imaging aneurysm vorticity mean measurement; Imaging aneurysm viscous dissipation measurement; Imaging aneurysm vortex coreline length measurement; Imaging aneurysm wall shear stress mean measurement; Imaging aneurysm wall shear stress maximum measurement; Imaging aneurysm wall shear stress minimum measurement; Imaging aneurysm shear concentration index value; Imaging aneurysm low wall shear stress percent value; Imaging aneurysm oscullatory shear stress mean value; Imaging aneurysm inflow mean rate; Imaging

			aneurysm inflow concentration index value **Supplemental:** All other CDEs
Vessel Imaging Transcranial CRF	Assessments and Examinations	Imaging Diagnostics	**Supplemental:** All CDEs

5. **Comparison to other Stroke standards** *(Are there any notable similarities/differences in the CDE recommendations as compared with other standards?)*
   Similar to prior process of original CDE development

6. **Issues unique to Stroke** *(Were there any issues encountered when developing the CDE standards which are unique to Stroke or which highlight a unique concern about Stroke data collection?)*
   Yes, episodic use or acute nature of data element availability.

7. **Unmet needs; unanswered questions** *(What unmet need / unanswered questions were identified via the CDE process in Stroke? What areas are in need of further research and development?)*
   Codification and practical simplification of CDE to enhance future use.

PATIENT INFORMATION

1) *Study ID number:
2) *Date and time of study (M M/D D/Y Y Y Y):
   (HH:MM, 24 hr clock):
3) NIH Stroke Scale (NIHSS) at time of study (0-42):[1]
4) Scan purpose (Select all that apply):
   - ☐ Diagnostic
   - ☐ Treatment
   - ☐ Post-treatment
   - ☐ Monitoring
   - ☐ Other, specify

TECHNICAL INFORMATION

1) Imaging modality (Select all that apply):
   - ☐ DSA
   - ☐ MRA/MRV
   - ☐ CTA/CTV
   - ☐ Cone Beam Computed Tomography (CBCT)
2) Digital Subtraction Angiography (DSA)
   a. Site of access:
      ☐ Brachial ☐ Femoral
      ☐ Radial ☐ Other
   b. Selective injections (Select all that apply in table below and side) :

1 Technical Information Table

Injection Site	Side
Arch	☐ N/A – Not present
Common Carotid	☐ Right ☐ Left ☐ Bilateral ☐ N/A – Not present
Internal Carotid	☐ Right ☐ Left ☐ Bilateral ☐ N/A – Not present
Vertebral	☐ Right ☐ Left ☐ Bilateral ☐ N/A – Not present
Subclavian	☐ Right ☐ Left ☐ Bilateral ☐ N/A – Not present

[1] NIHSS is also included on other Stroke CDE CRF Modules. This item should be pre-populated if initially collected elsewhere so as to avoid redundant data points.

3) Magnetic Resonance Angiography (MRA): (Select all that apply)
   - ☐ Head (Time of Flight - TOF)
   - ☐ Neck (TOF)
   - ☐ Contrast enhanced Head and Neck
   - ☐ Magnetic Resonance Venography (MRV) with contrast
   - ☐ Magnetic Resonance Venography (MRV) without contrast
4) Computer Tomography Angiography (Select all that apply):
   - ☐ Head
   - ☐ Neck
   - ☐ Computer Tomography Venography (CTV)

IMAGING FINDINGS

1) Aneurysm location (select all that apply):

☐ C1 cervical
☐ C2 petrous
☐ C3 lacerum
☐ C4 cavernous
☐ C5 clinoidal
☐ C6 – ophthalmic to PCOM
☐ C6 – PCOM to terminus
☐ PCOM
☐ A1
☐ ACOM
☐ A2
☐ M1 proximal to striate
☐ M1 distal to striate
☐ M2
☐ M3
☐ M4
☐ Vertebral origin
☐ Vertebral - cervical
☐ Vertebral – intracranial proximal to PICA
☐ Vertebral – distal to PICA
☐ Basilar – distal to AICA
☐ Basilar – mid
☐ Basilar – proximal to AICA
☐ P1
☐ P2
☐ P3
☐ SCA
☐ AICA
☐ PICA

**Side	Measurements	Details
☐ Right ☐ Left ☐ Midline	*Maximum diameter: *Height: *Width:	***Stenosis of pre-aneurysmal parent arteries? ☐ Yes ☐ No

**Side	Measurements	Details
	**Neck measurement: **Aspect ratio value: **Size ratio: **Bottleneck factor: Diameter of proximal parent artery: Diameter of distal parent artery: Number of sidewall branches:	***Contralateral stenocclusive vessel disease? ☐ Yes ☐ No Evidence of calcification? ☐ Yes ☐ No Evidence of thrombus? ☐ Yes ☐ No ☐ Unknown **Aneurysm shape/pathology: ☐ Saccular ☐ Fusiform ☐ Dissecting ***Shape at follow-up: ☐ Constant ☐ Change in shape *Morphology type: ☐ Regular ☐ Bleb ☐ Daughter-sac, multi-lobed aneurysm **Increase of aneurysm diameter ≥ 1 mm in any direction since last imaging? ☐ Yes: ☐ Growth regarding largest diameter in any direction (mm): ☐ No

2) **Has there been any de novo formation of an aneurysm since the last imaging?

☐ Yes
☐ No

General Instructions

This CRF contains data that would be collected when an imaging study is performed using angiography to examine the blood vessels of the body. There are separate sections to record arterial findings and venous findings.

Important note: A subset of the data elements included on this CRF Module is considered Core (i.e., strongly recommended for stroke clinical studies to collect if imaging studies are performed). The remaining data elements (i.e., non Core) are supplemental and should only be collected if the research team considers them appropriate for their study.

*Element is classified as Core if protocol includes imaging

** Element is classified as Supplemental – Highly Recommended

***Element is classified as Exploratory

The remaining data elements are Supplemental and should only be collected if the research team considers them appropriate for their study.

Specific Instructions

Please see the Data Dictionary for definitions for each of the data elements included in this CRF Module.

FINDINGS

1. Ventricle Findings

Table 2 Ventricle Findings

Ventricle	Ejection Fraction (%)	Systolic Function	End Diastolic Dimension	End Systolic Dimension	End Diastolic Volume (ml)	End Diastolic Volume Index (ml/m^2)	End Systolic Volume (ml)	End Systolic Volume Index (ml/m^2)	Septal thickness	Posterior Wall thickness	LV mass	LV mass index
a) Left Ventricle	Data to be entered by site	☐ Normal ☐ Abnormal	Data to be entered by site	Data to be entered by site	Data to be entered by site	Data to be entered by site	Data to be entered by site	Data to be entered by site	Data to be entered by site	Data to be entered by site	Data to be entered by site	Data to be entered by site
b) Right Ventricle	Data to be entered by site	☐ Normal ☐ Abnormal	Data to be entered by site	Data to be entered by site	Data to be entered by site	Data to be entered by site	Data to be entered by site	Data to be entered by site	Data to be entered by site	Data to be entered by site	Data to be entered by site	Data to be entered by site

2. Left Ventricular Non-Compaction Details

Table 3 Left Ventricular Non-Compaction Details

Non-Compaction?	Number of Trabeculations	Ratio of Noncompacted LV Myocardial Thickness to Compacted LV Myocardial Thickness at End-Diastole	Position
☐ Present ☐ Absent (leave rest of table blank)	Data to be entered by site	Data to be entered by site	☐ Lateral ☐ Apical ☐ Septal ☐ Free wall ☐ Not specified

3. Atrial size
    a. Area: Right

b. Area: Left

4. Gadolinum-based contrast used? ☐ Yes ☐ No ☐ Unknown

Myocardial Delayed Enhancement for Ventricles

Table 4 Myocardial Delayed Enhancement for Ventricles

Ventricle	Myocardial Scar
a) Left Ventricle	☐ Present ☐ Absent
b) Right Ventricle	☐ Present ☐ Absent

5. Indicate in what segment the myocardial scar is present.

Figure 1 Myocardial scar location

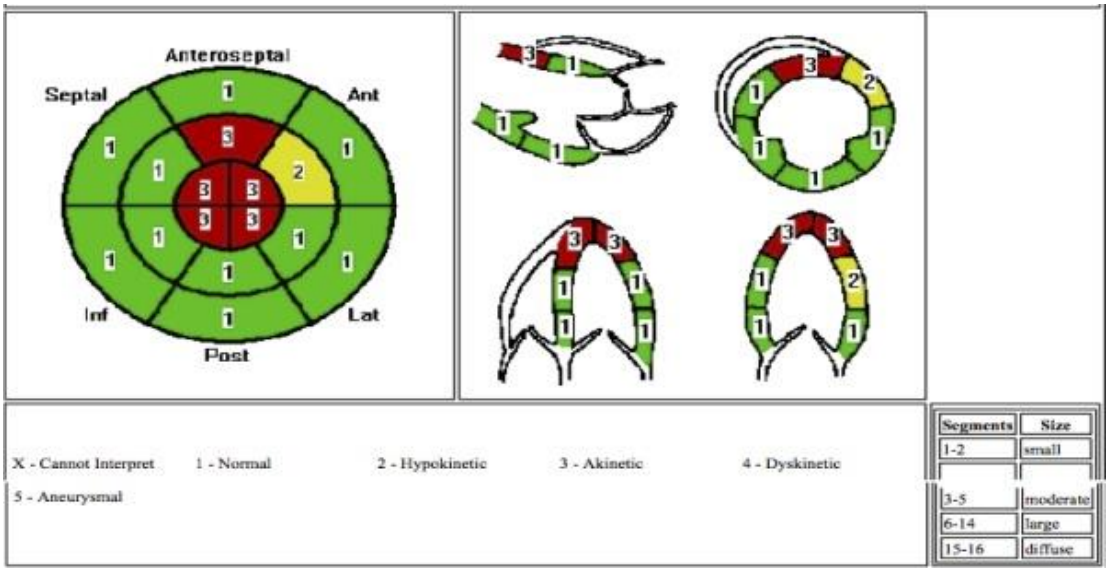

6. Veins and Other Cardiac Findings

Table 5 Veins and Other Cardiac Findings

Other Findings	Structure	Comments
a) Aorta	☐ Normal ☐ Abnormal	Data to be entered by site
b) Pulmonary Venous Anatomy	☐ Normal ☐ Abnormal	Data to be entered by site
c) Systemic Venous Anatomy	☐ Normal ☐ Abnormal	Data to be entered by site
d) Pericardium	☐ Normal ☐ Abnormal	Data to be entered by site
e) Extracardiac Findings	☐ Normal ☐ Abnormal	Data to be entered by site
f) Intracardiac Findings	☐ Thrombosis – Right ☐ Thrombosis – Left ☐ Mass – Right ☐ Mass – Left ☐ Device – Right ☐ Device – Left	Data to be entered by site

7. Quality of Study:

☐ Technically difficult ☐ Suboptimal ☐ Fair ☐ Good ☐ Excellent

8. Overall Impression:

General Instructions

This form contains data elements that are collected to assess ventricular volume and function, as well as delineating myocardial involvement by delayed enhancement imaging.

Specific Instructions

Please see the Data Dictionary for definitions for each of the data elements included in this CRF Module.

- Ejection fraction – Answer for left ventricle. Record value as a percent (%). Value for right ventricle is optional.
- Ventricle end systolic dimension – Answer for left ventricle. Record value in millimeters (mm). Value for right ventricle is optional.
- End diastolic dimension – Answer for left ventricle. Record value in millimeters (mm). Value for right ventricle is optional.
- End systolic dimension – Answer for left ventricle. Record value in millimeters (mm). Value for right ventricle is optional.
- End diastolic volume – Answer for left ventricle. Record value in milliliters (ml). Value for right ventricle is optional.
- End diastolic volume index number – Answer for left ventricle. Record value in milliliters per meter squared (ml/m2). Value for right ventricle is optional.
- End systolic volume – Answer for left ventricle. Record value in milliliters (ml). Value for right ventricle is optional.
- End systolic volume index number – Answer for left ventricle. Record value in milliliters per meter squared (ml/m2). Value for right ventricle is optional.
- Left ventricle mass – Record the value as an integer to two decimal places in grams (gm).

1. Was an echocardiogram completed? ☐ Yes ☐ No ☐ Unknown

   i. If Yes, indicate date of echocardiogram:

2. Left ventricular end-diastolic posterior wall thickness (PWTd): centimeters: z-score:

3. Left ventricular end-diastolic septal thickness (LVSTd): centimeters: z-score:

4. Left ventricular end-diastolic internal dimension (LVIDd): centimeters: z-score:

5. Left ventricular end-systolic internal dimension (LVIDs): centimeters: z-score:

6. Left atrial antero-posterior dimension: centimeters: z-score:

7. Right Ventricular Wall Thickness in diastole (RVWTd): centimeters: z-score:

8. Right atrial enlargement: ☐ Present ☐ Absent

9. Right ventricular enlargement: ☐ Present ☐ Absent

10. Right ventricular systolic dysfunction: ☐ Present ☐ Absent

11. Left Ventricle Mass (index): grams: z-score:

12. Does subject have left ventricular hypertrophy? ☐ Yes ☐ No ☐ Unknown

13. Was the subject's left ventricle dilated? ☐ Yes ☐ No ☐ Unknown

14. Was there a Left Ventricular Outflow Tract (LVOT) obstruction? ☐ Yes ☐ No ☐ Unknown

15. If Yes, indicate:

    i. Peak systolic pressure gradient (millimeters of mercury):
    ii. Mean pressure gradient (millimeters of mercury):

16. Left ventricular ejection fraction (percent):

17. Degree of Aortic Regurgitation (AR): ☐ None ☐ Mild ☐ Moderate ☐ Severe

18. Degree of Mitral Regurgitation (MR): ☐ None ☐ Mild ☐ Moderate ☐ Severe

19. Degree of Tricuspid Regurgitation (TR): ☐ None ☐ Mild ☐ Moderate ☐ Severe

20. Fractional shortening (percent):

21. Early mitral inflow velocity (E) (centimeters per second):

22. Late Mitral Inflow Velocity (A) (centimeters per second):

23. Mitral Inflow (E) deceleration time (milliseconds):

24. Tissue Doppler:

Septum:

i. E' velocity (centimeters per second):
ii. A' velocity (centimeters per second):
iii. S velocity (centimeters per second):

Mitral annulus:

i. E' velocity (centimeters per second):
ii. A' velocity (centimeters per second):
iii. S velocity (centimeters per second**):**

General Instructions

This form contains data elements that are collected to measure heart function.

Specific Instructions

Please see the Data Dictionary for definitions for each of the data elements included in this CRF Module.

Data and time performed – The date/time should be recorded to the level of granularity known (e.g., year, year and month, complete date plus hours and minutes, etc.) and in the format acceptable to the study database.

PWTd measurement - Record the value as an integer out to one decimal place in centimeters (cm). Age and weight related. Adult normal range: 0.6 – 1.1 cm. Child normal range: 0.4 – 0.8 cm.

PWTD z- score – Record the z-score with up to two decimal places. Z-scores are a means of expressing the deviation of a given measurement from the size or age specific population mean and can be useful in pediatric populations. Online echocardiogram z-score calculators are available.

LVSTd measurement – Record the value as an integer out to one decimal in centimeters (cm). Age and weight related. Adult normal range: 0.6 – 1.1 cm. Child normal range: 0.3 – 0.8 cm.

LVSTd z-score – Record the z-score with up to two decimal places.

LVIDd measurement – Record the value as an integer out to one decimal place in centimeters (cm). Age and weight related. Adult normal range: 3.5 – 5.7 cm. Child normal range: 3.3 – 5.2 (25 kg and above child).

LVIDd z-score – Record the z-score with up to two decimal places

LVIDs measurement – Record the value as an integer out to one decimal place in centimeters (cm).
Age and Weight related.

LVIDs z-score – Record the z-score with up to two decimal places

Left atrial antero-posterior dimension measurement – Record the value in centimeters (cm).

Left atrial antero-posterior dimension z-score – Record the z-score with up to two decimal places

RVWTd measurement –Record the value as an integer out to one decimal place in centimeters (cm).

RVWTd z-score – Record the z-score with up to two decimal places

Left ventricle mass measurement –Record the value as an integer out to one decimal place in grams (gm).

Left ventricle mass z-score – Record the z-score with up to two decimal places

Peak systolic pressure gradient measurement –Record the value as an integer in mmHg. This measurement should be recorded if the participant/subject is found to have a LVOT obstruction.

Mean pressure gradient measurement –Record the value as an integer in mmHg. This measurement should be recorded if the participant/subject is found to have a LVOT obstruction.
Left ventricle ejection fraction measurement – Record the value as a percent (%).
Normal range: 54% – 75%

Fractional shortening measurement – Record the value as a percent (%)

Early mitral inflow velocity measurement –Record the value as an integer to two decimal places in cm/s. Age related values.

Tissue doppler septum E' velocity measurement –Record the early diastolic myocardial relaxation value as an integer to two decimal places in cm/s. Age related values.

Tissue doppler septum A' velocity measurement – Record the active atrial contraction in late diastole value as an integer to two decimal places in cm/s. Age related values.

Tissue doppler septum S' velocity measurement – Record the myocardial contraction value as an integer to two decimal places in cm/s. Age related values.

Tissue doppler mitral annulus E' velocity measurement – Record the early diastolic myocardial relaxation value as an integer to two decimal places in cm/s. Age related values.

Tissue doppler mitral annulus A' velocity measurement – Record the active atrial contraction in late diastole value as an integer to two decimal places in cm/s. Age related values.

Tissue doppler mitral annulus S velocity measurement – Record the early diastolic myocardial value as an integer to two decimal places in cm/s. Age related values.

1. Date of Echocardiography:
2. Left atrial antero-posterior dimension: cm: z-score**:**
3. Left atrial enlargement?: ☐ Present ☐ Absent
   Left atrium view: ☐ M-Mode ☐ Parasternal long axis

   Left atrial dimension: cm^2

   Left atrial volume: ml

   Left atrial area (measured from apical 4-chamber view): cm^2
4. Left Ventricle Trabeculations? ☐ Present ☐ Absent
   If present,

   a. Are any of these more than 2:1? ☐ Yes ☐ No
   b. Where were they positioned?
      ☐ Lateral ☐ Apical ☐ Septal ☐ Free wall ☐ Not specified

Table 6 Structure and Function valves (more than mild)

Valve	Stenosis	Regurgitation	Comments
Tricuspid valve disease	☐ None ☐ Mild ☐ Moderate ☐ Severe	☐ None ☐ Mild ☐ Moderate ☐ Severe	

Valve	Stenosis	Regurgitation	Comments
Mitral valve disease	☐ None ☐ Mild ☐ Moderate ☐ Severe	☐ None ☐ Mild ☐ Moderate ☐ Severe	
Aortic valve disease	☐ None ☐ Mild ☐ Moderate ☐ Severe	☐ None ☐ Mild ☐ Moderate ☐ Severe	
Pulmonic valve disease	☐ None ☐ Mild ☐ Moderate ☐ Severe	☐ None ☐ Mild ☐ Moderate ☐ Severe	

5. Mitral valve prolapse? ☐ Yes ☐ No
6. Doppler:
   a. Mitral E velocity: m/s
   b. Mitral A velocity: m/s
   c. Mitral annular E' velocity: cm/s
7. Left ventricular hypertrophy: ☐ Present ☐ Absent
8. Left ventricular concentric remodeling (size normal): ☐ Present ☐ Absent
9. Right atrial enlargement?: ☐ Present ☐ Absent
10. Right ventricular enlargement: ☐ Present ☐ Absent
11. Right ventricular systolic dysfunction: ☐ Present ☐ Absent

Table 7 Ventricle Findings

Findings	Left Ventricle	Right Ventricle
Ejection Fraction (%)		
Fractional Shortening (%)		

Findings	Left Ventricle	Right Ventricle
Function	☐ Normal ☐ Abnormal	☐ Normal ☐ Abnormal
Wall motion abnormalities?[2]	☐ Yes ☐ No	☐ Yes ☐ No
End Diastolic Internal Dimension		
End Systolic Internal Dimension		
End Diastolic Volume (mL)		
End Diastolic Volume Index (mL/m2)		
End Systolic Volume (mL)		
End Systolic Volume Index (mL/m2)		
End Diastolic Septal Thickness IVSTd		
End diastolic Posterior Wall Thickness PWTd		
LV Mass		
LV Mass Index		
Non-compaction?	☐ Present ☐ Absent	☐ Present ☐ Absent

If Yes, attach lab printout with wall motion abnormalities and trabeculation.

12. Intracardiac findings (check all that are present):
    ☐ Device lead ☐ Thrombosis ☐ Mass
13. Right ventricular systolic pressure (estimate): mmHg (plus right atrial pressure):
    Pressure estimated by: ☐ TR ☐ Other, specify
14. Pericardial effusion/abnormality: ☐ Yes ☐ No
    If yes, describe:
15. Quality of Study:
    ☐ Technically Difficult ☐ Suboptimal ☐ Fair ☐ Good ☐ Excellent
16. Echocardiogram Results (check only one):

[2] If Yes, attach lab printout with wall motion abnormalities and trabeculation.

☐ Normal

☐ πBorderline

☐ πAbnormal, Not Clinically Significant

☐ πUnable to evaluate

☐ πAbnormal, Clinically Significant

π For any Echocardiogram result that is not Normal, provide comments:

General Instructions

This form contains data elements that are collected to measure heart function.

Specific Instructions

Please see the Data Dictionary for definitions for each of the data elements included in this CRF Module.

- Date of Echocardiography - Record the date in the format yyyy-mm-dd. If any part of the date is Unknown, record as 9999.
- Left atrial area – This value is measured from the apical 4-chamber view
- Right ventricular systolic pressure – This value is an estimated value of the right ventricular systolic pressure.
- Echocardiogram Results – For any result that is not Normal, provide comments

TECHNICAL INFORMATION

1. Imaging study date and time // (24 hour clock)
2. Imaging modality (choose one):
   - ☐ Non-contrast CT
   - ☐ X-Ray Angiography
   - ☐ Contrast CT
   - ☐ MRI
   - ☐ CT Angiography
   - ☐ Digital Subtraction Angiography (DSA)
   - ☐ Magnetic Resonance Angiography (MRA)/Magnetic Resonance Venography (MRV)
   - ☐ Computer Tomography Angiography (CTA)/Computer Tomography Venography (CTV)
   - ☐ Cone Beam Computed Tomography (CBCT)
3. MRI field strength (choose one):
   ☐ 1.5T ☐ 3.0T ☐ 4.0T ☐ 7.0T ☐ Other, specify:
4. Imaging scanner manufacturer name (choose one):
   - ☐ Agfa
   - ☐ Carestream
   - ☐ GE
   - ☐ Hitachi
   - ☐ Hologic
   - ☐ Konica Minolta
   - ☐ Philips
   - ☐ Siemens
   - ☐ Toshiba
   - ☐ Other, specify
5. Imaging scanner model name:
6. Imaging scanner software version number:
7. Imaging sequence (choose all that apply):
   - ☐ T1
   - ☐ DWI
   - ☐ DTI
   - ☐ ASL
   - ☐ T2
   - ☐ GRE
   - ☐ MRS
   - ☐ FLAIR
   - ☐ SWI
   - ☐ PWI
   - ☐ Other, specify

General Instructions

This CRF contains data that would be collected when an imaging study is performed.

The data elements are supplemental and should only be collected if the research team considers them appropriate for their study.

Specific Instructions

Please see the Data Dictionary for definitions for each of the data elements included in this CRF Module.

PATIENT INFORMATION

1) *Study ID number:
2) *Date and time of study (M M/D D/Y Y Y Y):
   (HH:MM, 24 hr clock):
3) NIH Stroke Scale (NIHSS) at time of scan (0-42)[3]:
4) Scan purpose (Select all that apply):

☐ Diagnostic
☐ Post-treatment
☐ Follow-up
☐ Monitoring
☐ Other, specify

TECHNICAL INFORMATION

1) Imaging modality (Select all that apply):

☐ MRI:

~~a. MRI details:~~
b. MRI Scanner strength:

☐ 1.5 T
☐ 4.0 T
☐ Other, specify:
☐ 3.0 T
☐ 7.0 T

c. MRI Sequences acquired and slice thickness (Select all that apply, if selected provide slice thickness and gap:)

☐ DWI / ADC (mm):
☐ GRE (mm):
☐ SWI (mm):
☐ PWI (mm):
☐ FLAIR (mm):
☐ Post-contrast FLAIR (mm):
☐ T1-weighted (mm):
☐ T2-weighted (mm):
☐ Post-contrast T1-weighted (mm):
☐ COW MRA
☐ TOF Neck MRA
☐ CE MRA
☐ Other, specify (mm):

[3] NIHSS is also included on other Stroke CDE CRF Modules. This item should be pre-populated if initially collected elsewhere so as to avoid redundant data points.

☐ CT ~~details~~:

a. Scanner number of slices:
b. Sequences acquired and slice thickness:

☐ Non-contrast head CT(mm):

☐ Perfusion CT (mm):

☐ CT angiogram head (mm):

☐ CT angiogram neck (mm):

☐ Postcontrast head CT (mm):

☐ Other, specify (mm):

~~c.Was CTA source image used?~~

~~☐ Yes~~ ~~☐ No~~

~~d. Type of CT scan (Select all that apply, if selected provide slice thickness):~~

~~☐ CT non-contrast (mm):~~ ~~☐ CT post-contrast (mm):~~

~~e. Window settings: window:~~
~~f. level:~~

~~2) Read type (Select all that apply):~~

~~☐ Local read~~ ~~☐ Central read~~

~~☐ Local report~~

~~3) Reader blinded to clinical data:~~

~~☐ Yes~~

~~☐ No~~

~~4) Study technically satisfactory:~~

~~☐ Yes~~ ~~☐ No~~

ISCHEMIC DISEASE

1) Acute infarct(s) present:

☐ Definitely present ☐ Definitely absent

☐ Equivocal

~~Level of confidence:~~

~~☐ Definite AICS – confirmation of infarction or relevant vascular lesion~~

~~☐ Probable AICS – clinical stroke syndrome but imaging not sensitive to pick up expected abnormality given duration of deficit, timing and quality of imaging. Other causes ruled out.~~

~~☐ Possible AICS – syndrome that may have been due to cerebral ischemia but other causes not ruled out and diagnostic studies were not performed or were negative and sensitive for ischemic pathology of the given duration, severity and location.~~

~~Diagnosis of stroke / TIA:~~

~~a. Imaging positive:~~

~~☐ Yes~~ ~~☐ No~~

~~b. Symptoms resolve:~~

~~☐ Yes~~ ~~☐ No~~

~~c. Symptoms resolve < 24 Hrs:~~

~~☐ Yes~~ ~~☐ No~~

2) Number of acute infarcts:
~~Infarcts type~~

a. If more than one, are they all in one vascular territory?

☐ Yes ☐ Not applicable

☐ No (If No skip to 3)

b. Circulations involved (Select all that apply):

☐ Anterior ☐ Posterior

c. Structures involved (Select all that apply):

☐ Right hemisphere ☐ Brainstem

☐ Left hemisphere ☐ Cerebellum

3) Location of acute infarct (Select all that apply. N/A – Not present should be default response for each region):

Brain Region Table

Brain Region	Side
Frontal lobe	☐ Right ☐ Left ☐ Bilateral ☐ N/A – Not present
Parietal lobe	☐ Right ☐ Left ☐ Bilateral ☐ N/A – Not present
Temporal lobe	☐ Right ☐ Left ☐ Bilateral ☐ N/A – Not present
Occipital lobe	☐ Right ☐ Left ☐ Bilateral ☐ N/A – Not present

Brain Region	Side
Insula	☐ Right ☐ Left ☐ Bilateral ☐ N/A – Not present
Cerebellum	☐ Right ☐ Left ☐ Bilateral ☐ N/A – Not present
Pons	☐ Right ☐ Left ☐ Bilateral ☐ N/A – Not present
Midbrain	☐ Right ☐ Left ☐ Bilateral ☐ N/A – Not present
Medulla	☐ Right ☐ Left ☐ Bilateral ☐ N/A – Not present
Corona radiata	☐ Right ☐ Left ☐ Bilateral ☐ N/A – Not present
Anterior limb IC	☐ Right ☐ Left ☐ Bilateral ☐ N/A – Not present
Posterior limb IC	☐ Right ☐ Left ☐ Bilateral ☐ N/A – Not present
Caudate	☐ Right ☐ Left ☐ Bilateral ☐ N/A – Not present
Globus Pallidus	☐ Right ☐ Left ☐ Bilateral ☐ N/A – Not present
Putamen	☐ Right ☐ Left ☐ Bilateral ☐ N/A – Not present
Thalamus	☐ Right ☐ Left ☐ Bilateral ☐ N/A – Not present

4) Vascular distribution (Select all that apply. N/A – Not present should be default response for each region.):

Vascular Territory Table

Vascular Territory	Side
ICA	☐ Right ☐ Left ☐ Bilateral ☐ N/A – Not present
ACA	☐ Right ☐ Left ☐ Bilateral ☐ N/A – Not present
M1	☐ Right ☐ Left ☐ Bilateral ☐ N/A – Not present
M2 and beyond	☐ Right ☐ Left ☐ Bilateral ☐ N/A – Not present
Lenticulostriates	☐ Right ☐ Left ☐ Bilateral ☐ N/A – Not present
PCA	☐ Right ☐ Left ☐ Bilateral ☐ N/A – Not present
VB	☐ Right ☐ Left ☐ Bilateral ☐ N/A – Not present
Venous	☐ Right ☐ Left ☐ Bilateral ☐ N/A – Not present
~~Watershed~~Borderzone	☐ Right ☐ Left ☐ Bilateral ☐ N/A – Not present

5) Additional findings (Select all that apply):

☐ ~~Mass effect~~

☐ Malignant edema

☐ Hyperdense ~~vessel~~artery, specify:

☐ Hyperdense venous sinus or cortical vein, specify:

☐ ~~Loss of grey white differentiation~~

6) Acute ischemic lesion volume:
   a. Planimetric (cc) (Planimetric = specific total volume for all acute lesions):
   b. Lesion count:
   c. Indicate sequence (Select all that apply):

☐ DWI / ADC

☐ FLAIR

☐ Other, specify:

   d. Indicate method:

☐ Manually drawn

☐ Relative Threshold:

☐ Absolute Threshold:

7) 1/3 MCA territory involved:
☐ Yes ☐ Not applicable

☐ No

ASPECT Score Figure

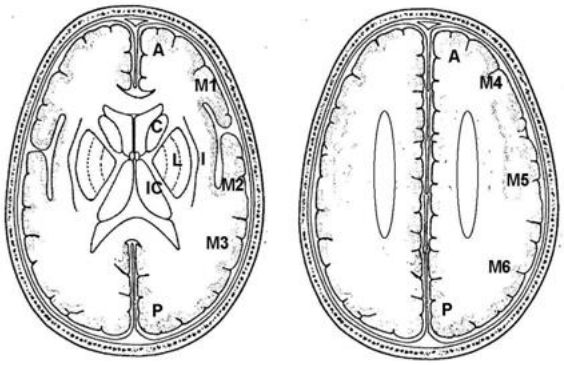

8) ASPECT Score:
Segmental assessment of the following MCA territory (0=~~No~~Involved, 1=~~Yes~~Not involved):

a. C=caudate (0, 1):
b. L=lentiform (0, 1):
c. IC=internal capsule (0, 1):
d. I=insular ribbon (0, 1):
e. M1=anterior MCA cortex (0, 1):
f. M2=MCA cortex lateral to insular ribbon (0, 1):
g. M3=posterior MCA cortex (0, 1):
h. M4=anterior superior to M1, rostral to basal ganglia (0, 1):
i. M5=lateral superior to M2 rostral to basal ganglia (0, 1):
j. M6=posterior superior to M3, rostral to basal ganglia (0, 1):
k. Total Score (0-10, sum of A-J above):

9) Chronic Infarct(s):
a. Present?
☐ Yes ☐ No (Skip to 10)

b. If Yes, number of chronic infarcts:
☐ Zero
☐ Single
☐ Multiple

c. If Yes, location(s) of chronic infarcts (Select all that apply. N/A – Not present should be default response for each region):

8 Chronic Infarcts Location Table

Brain Region	Side
Frontal lobe	☐ Right ☐ Left ☐ Bilateral ☐ N/A – Not present

Brain Region	Side
Parietal lobe	☐ Right ☐ Left ☐ Bilateral ☐ N/A – Not present
Temporal lobe	☐ Right ☐ Left ☐ Bilateral ☐ N/A – Not present
Occipital lobe	☐ Right ☐ Left ☐ Bilateral ☐ N/A – Not present
Insula	☐ Right ☐ Left ☐ Bilateral ☐ N/A – Not present
Cerebellum	☐ Right ☐ Left ☐ Bilateral ☐ N/A – Not present
Pons	☐ Right ☐ Left ☐ Bilateral ☐ N/A – Not present
Midbrain	☐ Right ☐ Left ☐ Bilateral ☐ N/A – Not present
Medulla	☐ Right ☐ Left ☐ Bilateral ☐ N/A – Not present
Corona radiata	☐ Right ☐ Left ☐ Bilateral ☐ N/A – Not present
Anterior limb IC	☐ Right ☐ Left ☐ Bilateral ☐ N/A – Not present
Posterior limb IC	☐ Right ☐ Left ☐ Bilateral ☐ N/A – Not present
Caudate	☐ Right ☐ Left ☐ Bilateral ☐ N/A – Not present
Globus Pallidus	☐ Right ☐ Left ☐ Bilateral ☐ N/A – Not present
Putamen	☐ Right ☐ Left ☐ Bilateral ☐ N/A – Not present

Brain Region	Side
Thalamus	☐ Right ☐ Left ☐ Bilateral ☐ N/A – Not present

10) Leukoaraiosis on MRI:
   a. Sequence employed (Select all that apply):

☐ FLAIR

☐ T2-weighted

☐ Other, specify:

   b. Fazekas scale:
      i. Periventricular:
         0 = Absence

         1 = “Caps” or pencil lining

         2 = Smooth “halo”

         3 = Irregular periventricular hyperintensities extending into the deep white matter

      ii. Deep white matter:
         0 = Absence

         1 = Punctuate foci

         2 = Beginning confluence of foci

         3 = Large confluent areas

      iii. Total score (Sum of items I. and II):
   c. Modified Scheltens scale:
      Use the following for I. – IV:

         0 = No abnormalities

         1 = ≤ 3mm and the number of lesions (n) ≤ 5

         2 = ≤ 3mm and number of lesions (n) ≤ 6

         3 = 4 to 10mm and the number of lesions (n) ≤ 5

         4 = 4 to 10mm and the number of lesions (n) ≥ 6

         5 = ≥ 11mm and the number of lesions (n) ≥ 1

         6 = Confluent

      i. Frontal:
      ii. Parietal:
      iii. Occipital:
      iv. Temporal:
      Use the following for V. – VII:

         0 = No abnormalities

         1 = Periventricular hyperintensities ≤5mm

         2 = Periventricular hyperintensities > 5mm and ≤ 10

v. Occipital caps:
vi. Frontal caps:
vii. Periventricular bands:
viii. Total score (Sum of scores I. – VII):

d. Age Related White Matter Changes (ARWMC) scale:
Use the following for I. – IV.:

0 = No lesion

1 = Focal lesions

2 = Beginning confluence of lesions

3 = Diffuse involvement

i. Frontal:
ii. Parieto-occipital:
iii. Temporal:
iv. Infratentorial / Cerebellum:
v. Basal Ganglia:

Use the following for V:

0 = No lesion

1 = 1 focal lesion ≥ 5 mm

2 = > 1 focal lesion

3 = Confluent lesions

vi. Total score (Sum of scores I – V):

e. Volumetric measure (cc):

11) Leukoaraiosis on CT:
a. Van Swieetten Scale:
i. Anterior white matter:

☐ No lesion
☐ Lesions partly involving the white matter
☐ Lesions extending up to the subcortical region

ii. Posterior white matter:

☐ No lesion
☐ Lesions partly involving the white matter
☐ Lesions extending up to the subcortical region

b. Volumetric measure (cc):

HEMORRHAGE

1) Intraparenchymal hematoma:
a. Acute hematoma present:

☐ Yes
☐ No (Skip to 2)

b. Intracerebral hemorrhage (ICH) volume (ABC/2):
c. ICH volume (planimetric):
d. For MRI, indicate sequence employed (Select all that apply):

☐ GRE
☐ SWI
☐ Other, specify:

e. *Location of hematoma (Select all that apply. N/A – Not present should be default response for each region):

9 Lobar Region Table

Lobar Region	Side
Frontal	☐ Right ☐ Left ☐ Bilateral ☐ N/A – Not present
Parietal	☐ Right ☐ Left ☐ Bilateral ☐ N/A – Not present
Temporal	☐ Right ☐ Left ☐ Bilateral ☐ N/A – Not present
Occipital	☐ Right ☐ Left ☐ Bilateral ☐ N/A – Not present

10 Deep Region Table

Deep Region	Side
~~Subcortical white matter~~	~~☐ Right~~ ~~☐ Left~~ ~~☐ Bilateral~~ ~~☐ N/A – Not present~~
Caudate	☐ Right ☐ Left ☐ Bilateral ☐ N/A – Not present
Putamen	☐ Right ☐ Left ☐ Bilateral ☐ N/A – Not present
Globus Pallidus	☐ Right ☐ Left ☐ Bilateral ☐ N/A – Not present
Thalamus	☐ Right ☐ Left ☐ Bilateral ☐ N/A – Not present
Cerebellum	☐ Right ☐ Left ☐ Bilateral ☐ N/A – Not present
Midbrain	☐ N/A – Not present
Pons	☐ N/A – Not present
Medulla	☐ N/A – Not present

f. Perihematomal edema volume (cc):

g. For MRI, indicate sequence employed for perihematomal edema volume (Select all that apply):

☐ FLAIR

☐ T2-weighted

☐ Other, specify:

h. Positive spot sign (CT Only):

☐ Yes

☐ No

i. Spot sign score (CT Only):

11 Spot sign score Table

#	0 Points	1 Point	2 Points
Number of spot signs:	Data to be entered by site	☐ 1-2	☐ ≥ 3
Maximum axial dimension:	☐ 1-4 mm	☐ ≥ 5 mm	
Maximum attenuation:	☐ 120-179 HU	☐ ≥ 180 HU	

Total score (Summation of points from boxes selected above):

j. Chronic hematoma present:

☐ Yes, specify number: ☐ No

k. Microbleeds present:

☐ Yes ☐ No (Skip to 2)

i. Right lobar count:
ii. Left lobar count:
iii. Right deep count:
iv. Left deep count:
v. Brainstem count:
vi. Cerebellum count:

2) *Intraventricular hemorrhage (IVH) present:

☐ Yes ☐ No (Skip to 3)

a. Graeb IVH scale:
Use the following for I – II:

1= Trace amount of blood or mild bleeding;

2 = < Half of the ventricle filled with blood;

3= > Half of the ventricle filled with blood;

4= Ventricle expanded and filled with blood

i. Right lateral ventricle score:
ii. Left lateral ventricle score:

Use the following for III – IV:

1= Blood present without dilatation;

2= Ventricle expanded and filled with blood

iii. Third ventricle score:
iv. Fourth ventricle score:
v. Total score (Sum of scores I. – IV.; maximum score is 12):

b. *Volume (cc):

3) Subarachnoid hemorrhage (SAH) present:

☐ Yes ☐ No (Skip to 4)

a. Fisher grade:

☐ Grade 1: No hemorrhage evident

☐ Grade 2: SAH less than 1 mm thick

☐ Grade 3: SAH more than 1 mm thick

☐ Grade 4: SAH of any thickness with IVH or parenchymal extension

b. Modified Fisher scale:

☐ Grade 1: No hemorrhage evident ☐ Grade 2: SAH less than 1 mm thick

☐ Grade 3: SAH more than 1 mm thick

☐ Grade 4: SAH of any thickness with IVH or parenchymal extension

c. Hijdra scale (Select all that apply in table below):

12 Location Table

Location	Value
Frontal	☐ 0 ☐ 1 ☐ 2 ☐ 3
Lateral Sylvian Right	☐ 0 ☐ 1 ☐ 2 ☐ 3
Lateral Sylvian Left	☐ 0 ☐ 1 ☐ 2 ☐ 3
Basilar Sylvian Right	☐ 0 ☐ 1 ☐ 2 ☐ 3
Basilar Sylvian Left	☐ 0 ☐ 1 ☐ 2 ☐ 3
Suprasellar Right	☐ 0 ☐ 1 ☐ 2 ☐ 3
Suprasellar Left	☐ 0 ☐ 1 ☐ 2 ☐ 3
Ambient Right	☐ 0 ☐ 1 ☐ 2 ☐ 3
Ambient Left	☐ 0 ☐ 1 ☐ 2 ☐ 3
Quadrigeminal	☐ 0 ☐ 1 ☐ 2 ☐ 3
Fourth Ventricle	☐ 0 ☐ 1 ☐ 2 ☐ 3
Lateral Ventricle Right	☐ 0 ☐ 1 ☐ 2 ☐ 3
Lateral Ventricle Left	☐ 0 ☐ 1 ☐ 2 ☐ 3

Total score:

4) Epidural Hematoma present:
☐ Yes ☐ No (Skip to 5)

a. ~~Grade~~Volume:
b. Thickness
~~☐ Grade 1: No Epidural Hematoma evident~~
~~☐ Grade 2: Epidural Hematoma less than 1 mm thick~~
~~☐ Grade 3: Epidural Hematoma more than 1 mm thick~~
~~☐ Grade 4: Epidural Hematoma of any thickness with IVH or parenchymal extension~~

~~c. Scale:~~
~~☐ Grade 1: No Epidural Hematoma evident~~
~~☐ Grade 2: Epidural Hematoma less than 1 mm thick~~
~~☐ Grade 3: Epidural Hematoma more than 1 mm thick~~
~~☐ Grade 4: Epidural Hematoma of any thickness with IVH or parenchymal extension~~

d. Location:

Frontal	☐ Right	☐ Left
Parietal	☐ Right	☐ Left
Temporal	☐ Right	☐ Left
Occipital	☐ Right	☐ Left
Posterior fossa	☐ Right	☐ Left

e. Hijdra scale (Select all that apply in table below):
Location Table

Location	Value
Right	☐ 0 ☐ 1 ☐ 2 ☐ 3
Left	☐ 0 ☐ 1 ☐ 2 ☐ 3
Bilateral	☐ 0 ☐ 1 ☐ 2 ☐ 3

Total score:

f. Hijdra scale (Select all that apply in table below):
☐ Likely venous (due to association with adjacent bony injury/fracture, venous sinus, size, distribution, timing)

☐ Likely arterial (due to "swirl", different densities, location near major dural artery)

5) Subdural Hematoma present:
☐ Yes ☐ No (Skip to 6)

a. Volume:
b. Thickness:

c. Location:

Frontal	☐ R	☐ L
Parietal	☐ R	☐ L
Temporal	☐ R	☐ L
Occipital	☐ R	☐ L
Interhemispheric supratentorial	☐ Anterior (frontoparietal)	☐ Posterior (occipital)
Tentorial	☐ R	☐ L
Posterior fossa	☐ R	☐ L

d. Hijdra scale (Select all that apply in table below):

7 **Location Table**

Location	Value
Right	☐ 0 ☐ 1 ☐ 2 ☐ 3
Left	☐ 0 ☐ 1 ☐ 2 ☐ 3
Midline	☐ 0 ☐ 1 ☐ 2 ☐ 3
Bilateral	☐ 0 ☐ 1 ☐ 2 ☐ 3

e. Subdural hematoma type ~~present~~:
~~☐ Yes~~ ~~☐ No (Skip to 5)~~

~~f. Type:~~
☐ Subacute ☐ Chronic

☐ Acute

~~g. Location:~~
~~☐ Right~~ ~~☐ Bilateral~~

~~☐ Left~~

~~6) Epidural Hematoma Present:~~
~~☐ Yes~~ ~~☐ No (Skip to 6)~~

~~If YES, Location:~~

~~☐ Right~~ ~~☐ Left~~

☐ ~~Bilateral~~

7) Hemorrhagic Transformation:
   a. Present?

☐ Yes

☐ No (Skip 7B-C)

☐ Unsure (Possible Contrast Staining)

   b. ~~Radiologic~~ Imaging type:

☐ HI-1(Hemorrhagic infarct type 1; small petechiae along the margins of the infarct)

☐ HI-2(Hemorrhagic infarct type 2; more confluent petechiae within the infarct area but without space-occupying effect)

☐ PH-1(Primary intracerebral hemorrhage type 1; blood clot(s) NOT exceeding 30% of the infarct area with some mild space occupying effect)

☐ PH-2 (Primary intracerebral hemorrhage type 2; blood clots exceeding 30% of the infarct area with substantial space occupying effect)

☐ RPH-1 (Remote primary intracerebral hemorrhage type 1; small or medium sized blood clots located remote from the actual infarct; a mild space occupying effect could be present)

☐ RPH-2 (Remote primary intracerebral hemorrhage type 2; large confluent dense blood clots in an area remote from the actual infarct; substantial space occupying effect might be present)

☐ SAH (Subarachnoid hemorrhage)

☐ IVH (Intraventricular hemorrhage)

   ~~c. Symptomatic type: (Select all that apply)~~

☐ ~~Spontaneous intracerebral hemorrhage (SICH) adjudicated - Neurologic deterioration, as indicated by an NIHSS score that was higher by 4 points or more than the value at baseline or the lowest value in the first 7 days, or any hemorrhage leading to death, with the hemorrhage identified by adjudicators as the predominant cause of the neurologic deterioration.~~

☐ ~~SICH highly probable - Local or remote parenchymal hematoma type 2, and neurologic deterioration, as indicated by a score on the NIHSS that was higher by 4 points or more than the baseline value or the lowest value between baseline and 24 hours, or hemorrhage leading to death.~~

☐ ~~SICH possible - Any decline in neurologic status associated with any newly imaged hemorrhage, or suspected hemorrhage in a patient who did not undergo repeat imaging.~~

☐ ~~None of the above~~

ADDITIONAL FINDINGS

1) Any midline shift present?

☐ ~~Yes~~Absent

☐ Present

☐ Indeterminate

☐ ~~No (Skip to 2)~~

   ~~a. Midline shift:~~

☐ ~~Yes~~

☐ ~~No~~

If ~~yes~~present, specify (mm):

   ~~b. Septal shift:~~

~~☐ Yes~~ ~~☐ No~~

~~If yes, specify (mm):~~

~~c. Pineal shift:~~

~~☐ Yes~~ ~~☐ No~~

~~If yes, specify (mm):~~

2) Herniation present?

☐ Yes ☐ No (Skip to 3)

a. Location:

☐ Subfalcine ☐ Uncal right

☐ Uncal left

☐ Tonsillar

☐ Transcalvarial

3) Hydrocephalus:

☐ Yes ☐ No

If yes, bicaudate index:

4) Arteriovenous malformation:

☐ Yes ☐ No

If yes, specify location:

5) Tumor present?

☐ Yes ☐ No

If yes, specify location:

6) Abscess present?

☐ Yes ☐ No

If yes, specify location:

7) Other ~~malformations present~~findings?

☐ Yes ☐ No

If yes, specify:

General Instructions

This CRF contains data that would be collected when an imaging study is performed to measure parenchyma. The data recorded attempt to divide the strokes into ischemic or hemorrhagic subtypes as distinction of hemorrhage versus infarction is the initial critical branch point in acute stroke triage.

Important note: A subset of the data elements included on this CRF Module is considered ~~Core~~ Supplemental – Highly Recommended (i.e., strongly recommended for stroke clinical studies to collect if imaging studies are performed). The remaining data elements ~~(i.e., non Core)~~ are supplemental and should only be collected if the research team considers them appropriate for their study.

Regional tables on the CRF include suggested potential regions. Researchers should choose which regions are needed based on the level of specificity needed for a study.

* Recommended as a Core Stroke CDE if protocol includes imaging

**Element is classified as Supplemental – Highly Recommended
***Element is classified as Exploratory

Specific Instructions

Please see the Data Dictionary for definitions for each of the data elements included in this CRF Module.

Hematoma questions are specific to hematoma type and should only be answered if applicable. Extra-axial hematoma questions should be answered if there is uncertainty regarding whether a hematoma is epidural or subdural.

Hijdra total scores should be calculated automatically based upon scores in the Hijdra scale table.

PATIENT INFORMATION

1) *Study ID number:
2) *Date and time of study (M M/D D/Y Y Y Y):
   (HH:MM, 24 hr clock):
3) NIH Stroke Scale (NIHSS) at time of scan (0-42):[4]
4) Scan purpose (Select all that apply):
   ☐Diagnostic
   ☐Post-treatment
   ☐Monitoring
   ☐Other, specify:

~~TECHNICAL INFORMATION~~

~~1) Imaging modality (Select all that apply):~~
~~☐MRI (Skip to 1A)~~ ~~☐CT (Skip to 1B)~~
~~a. MRI details:~~
~~i. Scanner strength:~~
~~ii. Slice thickness (mm):~~
~~b. CT details:~~
~~i. Slice thickness (mm):~~
~~2) Read type (Select all that apply):~~
~~☐Local read~~ ~~☐Central read~~
~~☐Local report~~
~~3) Reader blinded to clinical data:~~
~~☐Yes~~ ~~☐No~~
~~4) Study technically satisfactory:~~
~~☐Yes~~ ~~☐No~~

MRI FINDINGS

1) MR-based identification of core–Volumes:

13Volume Type Table

Volume Type	Threshold used to delineate abnormality	Value of threshold used to delineate abnormality	Defect volume (ml)
Diffusion Weighted Imaging (DWI) volume	☐Absolute ☐Relative	Data to be entered by site	Data to be entered by site
Apparent Diffusion Coefficient (ADC) volume	☐Absolute ☐Relative	Data to be entered by site	Data to be entered by site
~~Cerebral blood volume (CBV) defect volume~~	~~☐Absolute~~ ~~☐Relative~~	~~Data to be entered by site~~	~~Data to be entered by site~~
Other:	☐Absolute ☐Relative	Data to be entered by site	Data to be entered by site

2) MR-based identification of perfusion defect

[4] NIHSS is also included on other Stroke CDE CRF Modules. This item should be pre-populated if initially collected elsewhere so as to avoid redundant data points.

a. Method used for perfusion processing:

☐No deconvolution ☐Deconvolution with delay correction
☐Deconvolution without delay correction

b. Volumes:

14 Volume Type Table

Volume Type	Threshold used to delineate abnormality	Value of threshold used to delineate abnormality	Defect volume (ml)
Cerebral blood flow (CBV) defect volume	☐Absolute ☐Relative	Data to be entered by site	Data to be entered by site
Mean transit time lesion volume	☐Absolute ☐Relative	Data to be entered by site	Data to be entered by site
Time to peak lesion volume	☐Absolute ☐Relative	Data to be entered by site	Data to be entered by site
Time-to-maximum (Tmax) lesion volume	☐Absolute ☐Relative	Data to be entered by site	Data to be entered by site

3) MR-based identification of penumbra – Method used for penumbra calculation: (Select all that apply; if selected, provide volume)

☐DWI-CBF mismatch (volume): ☐Multiparametric model (volume):
☐DWI-MTT mismatch (volume): ☐Other, specify (volume):
☐DWI-TTP mismatch (volume):
☐DWI-Tmax mismatch (volume):

CT FINDINGS

1) Perfusion CT (PCT)-based identification of core
   a. Cerebral blood volume (CBV) defect volume:
      i. Threshold used to delineate abnormality:

☐Absolute ☐Relative

      ii. Value of threshold used to delineate abnormality:
      iii. Defect volume:
   b. Method used for penumbra calculation (Select all that apply; if selected, provide volume):

☐CBV (volume) : ☐Multiparametric Model (volume):

2) PCT-based identification of perfusion defect
   a. Method used for perfusion processing:

☐No deconvolution ☐Deconvolution with delay correction
☐Deconvolution without delay correction

   b. Volumes

15 Volume Type Table

Volume Type	Threshold used to delineate abnormality	Value of threshold used to delineate abnormality	Defect volume (ml)
Cerebral blood volume (CBV) defect volume	☐Absolute ☐Relative	Data to be entered by site	Data to be entered by site
Mean transit time lesion volume	☐Absolute ☐Relative	Data to be entered by site	Data to be entered by site
Time to peak lesion volume	☐Absolute ☐Relative	Data to be entered by site	Data to be entered by site
Time-to-maximum (Tmax) lesion volume	☐Absolute ☐Relative	Data to be entered by site	Data to be entered by site

3) PCT-based identification of penumbra–Method used for penumbra calculation (Select all that apply; if selected, provide volume):

☐CBV-CBF mismatch (volume):
☐CBV-MTT mismatch (volume):
☐CBV-TTP mismatch (volume):
☐CBV-Tmax mismatch (volume):
☐Multiparametric model (volume):
☐Other, specify (volume):

General Instructions

This CRF contains data that would be collected when an imaging study is performed to measure perfusion and penumbra. There are separate sections to record MRI findings and CT findings.

Important note: A subset of the data elements included on this CRF Module is considered Supplemental – Highly Recommended (i.e., strongly recommended for stroke clinical studies to collect if imaging studies are performed). The remaining data elements are Supplemental and should only be collected if the research team considers them appropriate for their study.

Specific Instructions

Please see the Data Dictionary for definitions for each of the data elements included in this CRF Module.

*Recommended as a Supplemental – Highly Recommended Stroke CDE if protocol includes imaging.

PATIENT INFORMATION

1) *Study ID Number:
2) *Date and time of study (M M/D D/Y Y Y Y):
   (HH:MM, 24 hr clock):
3) NIH Stroke Scale (NIHSS) at time of study (0-42):[5]
4) ~~Scan Purpose (Select all that apply):~~
   - ☐ ~~Diagnostic~~
   - ☐ ~~Post-treatment~~
   - ☐ ~~Monitoring~~

TECHNICAL INFORMATION

1) Probe:
   a. Type:
   b. Frequency (Hz):
2) Patient type:
   a. ☐ Asymptomatic
   b. ☐ Acute Stroke
      If Acute Stroke, indicate study type:
      ☐ Initial ☐ Follow-up 2
      ☐ Follow-up 1
   c. ☐ Chronic ~~Stroke~~
      i. ☐ Stroke:
         ☐ Hemisphere
         ☐ Eye
         ☐ Vertebrobasilar
      ii. ☐ TIA:
         ☐ Hemisphere
         ☐ Eye
         ☐ Vertebrobasilar
      iii. Laterality:
         ☐ Left
3) ☐ RightInterpretation site:
   a. ☐ Onsite
   b. ☐ Offsite
   If Offsite, indicate type:
   ☐ Video ☐ Digital
   ☐ Print
4) Contrast Agent:
   ☐ Yes ☐ No
   a. Agent:

[5] NIHSS is also included on other Stroke CDE CRF Modules. This item should be pre-populated if initially collected elsewhere so as to avoid redundant data points.

b. Type:

☐ Bolus
☐ Infusion
☐ Other, specify:

~~5) Read type (Select all that apply):~~
~~☐ Local read~~
~~☐ Local report~~
~~☐ Central read~~

~~6) Reader blinded to clinical data:~~
~~☐ Yes~~
~~☐ No~~

~~7) Study technically satisfactory:~~
~~☐ Yes~~
~~☐ No~~

FINDINGS

1) B-mode:
   a. CCA

16 Findings Table

Side	Right	Left
*Finding	☐ Normal (Skip to B) ☐ Plaque	☐ Normal (Skip to B) ☐ Plaque
*Echo pattern	☐ Homogeneous ☐ Heterogeneous	☐ Homogeneous ☐ Heterogeneous
*Surface	☐ Smooth ☐ Irregular	☐ Smooth ☐ Irregular
*Severity of plaque	☐ Mild ☐ Moderate ☐ Severe	☐ Mild ☐ Moderate ☐ Severe
Texture of plaque	:Data to be entered by site	: Data to be entered by site
Composition of plaque	: Data to be entered by site	: Data to be entered by site
Motion of plaque	: Data to be entered by site	: Data to be entered by site
Residual lumen	Data to be entered by site	Data to be entered by site
Thickness of plaque	Data to be entered by site	Data to be entered by site

   b. ICA

17 Findings Table

Side	Right	Left
*Finding	☐ Normal (Skip to C) ☐ Plaque	☐ Normal (Skip to B) ☐ Plaque
*Echo pattern	☐ Homogeneous ☐ Heterogeneous	☐ Homogeneous ☐ Heterogeneous
*Surface	☐ Smooth ☐ Irregular	☐ Smooth ☐ Irregular
Texture of plaque	Data to be entered by site	Data to be entered by site
Composition of plaque	Data to be entered by site	Data to be entered by site
Motion of plaque	Data to be entered by site	Data to be entered by site
Residual lumen	Data to be entered by site	Data to be entered by site
Thickness of plaque	Data to be entered by site	Data to be entered by site

   c. ECA

18: Findings Table

Side	Right	Left
*Finding	☐ Normal (Skip to 2) ☐ Plaque	☐ Normal (Skip to B) ☐ Plaque
*Echo pattern	☐ Homogeneous ☐ Heterogeneous	☐ Homogeneous ☐ Heterogeneous
*Surface	☐ Smooth ☐ Irregular	☐ Smooth ☐ Irregular
Texture of plaque	Data to be entered by site	Data to be entered by site
Composition of plaque	Data to be entered by site	Data to be entered by site
Motion of plaque	Data to be entered by site	Data to be entered by site
Residual lumen	Data to be entered by site	Data to be entered by site
Thickness of plaque	Data to be entered by site	Data to be entered by site

2) Color flow:
   a. CCA

19 Color flow Table

Side	Right	Left
*Angle	(degrees):	(degrees):
*Peak systolic velocity	(cm/sec):	(cm/sec):
*End diastolic velocity	(cm/sec):	(cm/sec):
*~~No s~~Signal?	☐ Yes ☐ No	☐ Yes ☐ No
*% Stenosis criterion	☐ PSV ☐ PSV/EDV ☐ Other, specify:	☐ PSV ☐ PSV/EDV ☐ Other, specify:
*% Stenosis	(%):	(%):
Volume flow rate	(ml/m):	(ml/m):
Other findings	☐ Turbulence ☐ Spectral broadening	☐ Turbulence ☐ Spectral broadening

   b. ICA

20 Color flow Table

Side	Right	Left
*Angle	(degrees):	(degrees):
*Peak systolic velocity	(cm/sec):	(cm/sec):
*End diastolic velocity	(cm/sec):	(cm/sec):
*~~No s~~Signal?	☐ Yes ☐ No	☐ Yes ☐ No
*% Stenosis criterion	☐ PSV ☐ PSV/EDV ☐ Other, specify:	☐ PSV ☐ PSV/EDV ☐ Other, specify:
*% Stenosis	(%):	(%):
CCA externalization	☐ Yes ☐ No	☐ Yes ☐ No
Power Doppler	☐ Flow ☐ No flow	☐ Flow ☐ No flow
Other findings	☐ Turbulence ☐ Spectral broadening	☐ Turbulence ☐ Spectral broadening

   c. ECA

21 Color flow Table

Side	Right	Left
*Angle	(degrees):	(degrees):
*Peak systolic velocity	(cm/sec):	(cm/sec):
*End diastolic velocity	(cm/sec):	(cm/sec):
*~~No s~~Signal?	☐ Yes ☐ No	☐ Yes ☐ No
*% Stenosis criterion	☐ PSV ☐ PSV/EDV ☐ Other, specify:	☐ PSV ☐ PSV/EDV ☐ Other, specify:
*% Stenosis	(%):	(%):
Other findings	☐ Turbulence ☐ Spectral broadening	☐ Turbulence ☐ Spectral broadening

d. Vertebral – origin:
☐Normal ☐Occluded
☐Stenosis ☐Reverse flow

e. Vertebral – interosseous:
☐Normal ☐Occluded
☐Stenosis ☐Reverse flow

3) Intima Media Thickness (IMT):

a. B-mode:
☐ Yes ☐ No

b. B-mode guided M mode:
☐ Yes ☐ No

c. Electronic caliper:
☐ Yes ☐ No

d. Edge detection algorithm:
☐ Yes, type: ☐ No (Skip to 5)

e. Timing:
☐ ECG Gating ☐Peak Systolic
☐ End Diastolic

f. Findings:

i. Mean and Max IMT:

22 Mean and Max IMT Table

Artery and side	Mean IMT Near-wall	Mean IMT Far-wall	I. Max IMT Near-wall	II. Max IMT Far-wall
CCA – right	(mm):	(mm):	(mm):	(mm):
CCA – left	(mm):	(mm):	(mm):	(mm):
Bulb – right	(mm):	(mm):	(mm):	(mm):
Bulb – left	(mm):	(mm):	(mm):	(mm):
ICA – right	(mm):	(mm):	(mm):	(mm):
ICA – left	(mm):	(mm):	(mm):	(mm):

ii. Diameters:

23 Diameters Table

Artery and side	Mean IMT Near-wall	Mean IMT Far-wall	III. Max IMT Near-wall	IV. Max IMT Far-wall
CCA – right	(mm):	(mm):	(mm):	(mm):
CCA – left	(mm):	(mm):	(mm):	(mm):

* Recommended as a ~~Core~~Supplemental-Highly Recommended Stroke CDE if protocol includes imaging

General Instructions

This CRF contains data that would be collected when an imaging study is performed using carotid ultrasound to examine the two large arteries in the neck. There are separate sections to record findings from B-mode and color flow imaging.

Important note: A subset of the data elements included on this CRF Module is considered ~~Core~~Supplemental-Highly Recommended (i.e., strongly recommended for stroke clinical studies to collect if imaging studies are performed). The remaining data elements (i.e., non Core) are supplemental and should only be collected if the research team considers them appropriate for their study.

Specific Instructions

Please see the Data Dictionary for definitions for each of the data elements included in this CRF Module.

PATIENT INFORMATION

5) *Study ID number:
6) *Date and time of study (M M/D D/Y Y Y Y):
(HH:MM, 24 hr clock):
7) NIH Stroke Scale (NIHSS) at time of study (0-42):[6]
8) Scan purpose (Select all that apply):
   - ☐ Diagnostic
   - ☐ Treatment
   - ☐ Post-treatment
   - ☐ Monitoring
   - ☐ Other, specify

TECHNICAL INFORMATION

5) Imaging modality (Select all that apply):
   - ☐ DSA
   - ☐ MRA/MRV
   - ☐ CTA/CTV
   - ☐ Cone Beam Computed Tomography (CBCT)
6) Digital Subtraction Angiography (DSA)
   a. Site of access:
      ☐ Brachial ☐ Femoral
      ☐ Radial ☐ Other
   b. Selective injections (Select all that apply in table below and side) :

24 Technical Information Table

Injection Site	Side
Arch	☐ N/A – Not present
Common Carotid	☐ Right ☐ Left ☐ Bilateral ☐ N/A – Not present
Internal Carotid	☐ Right ☐ Left ☐ Bilateral ☐ N/A – Not present
Vertebral	☐ Right ☐ Left ☐ Bilateral ☐ N/A – Not present
Subclavian	☐ Right ☐ Left ☐ Bilateral ☐ N/A – Not present

[6] NIHSS is also included on other Stroke CDE CRF Modules. This item should be pre-populated if initially collected elsewhere so as to avoid redundant data points.

7) Magnetic Resonance Angiography (MRA): (Select all that apply)
   - ☐ Head (Time of Flight - TOF)
   - ☐ Neck (TOF)
   - ☐ Contrast enhanced Head and Neck
   - ☐ Magnetic Resonance Venography (MRV) with contrast
   - ☐ Magnetic Resonance Venography (MRV) without contrast
8) Computer Tomography Angiography (Select all that apply):
   - ☐ Head
   - ☐ Neck
   - ☐ Computer Tomography Venography (CTV)

~~9) Read type (Select all that apply):~~
- ~~☐ Local read~~
- ~~☐ Local report~~
- ~~☐ Central read~~

~~10) Reader blinded to clinical data:~~
- ~~☐ Yes~~
- ~~☐ No~~

~~11) Study technically satisfactory:~~
- ~~☐ Yes~~
- ~~☐ No~~

FINDINGS

1) Arterial findings:
   a. Location:

- ☐ CCA origin
- ☐ CCA to bifurcation
- ☐ ICA at origin
- ☐ C1 cervical
- ☐ C2 petrous
- ☐ C3 lacerum
- ☐ C4 cavernous
- ☐ C5 clinoidal
- ☐ C6 – ophthalmic to PCOM
- ☐ C6 – PCOM to terminus
- ☐ A1
- ☐ A2
- ☐ M1 proximal to striate
- ☐ M1 distal to striate
- ☐ M3 multiple
- ☐ M4 single
- ☐ M4 multiple
- ☐ Vertebral origin
- ☐ Vertebral – cervical
- ☐ Vertebral – intracranial proximal to PICA
- ☐ Vertebral – distal to PICA
- ☐ Basilar – proximal
- ☐ Basilar – mid
- ☐ Basilar – distal
- ☐ PCOM
- ☐ P1
- ☐ P2
- ☐ P3

☐ M2 single
☐ M2 multiple
☐ M3 single
☐ SCA
☐ AICA
☐ PICA

b. Findings~~, Cause, Symptomology~~:

1Findings Table

Side	Right	Left
Findings	☐ Normal ☐ Occlusion ☐ Aneurysm ☐ Stenosis ☐ AVM ☐ Other ☐ Not visualized	☐ Normal ☐ Occlusion ☐ Aneurysm ☐ Stenosis ☐ AVM ☐ Other ☐ Not visualized
~~Cause~~	~~☐ Atherosclerotic~~ ~~☐ Embolic~~ ~~☐ Other~~ ~~☐ Unknown~~	~~☐ Atherosclerotic~~ ~~☐ Embolic~~ ~~☐ Other~~ ~~☐ Unknown~~
~~Symptomology~~	~~☐ Symptomatic~~ ~~☐ Asymptomatic~~ ~~☐ Indeterminate~~	~~☐ Symptomatic~~ ~~☐ Asymptomatic~~ ~~☐ Indeterminate~~

~~2) TIMI Scale – Individual Vessel Score~~

~~☐ 0 - No perfusion~~
~~☐ 1 - Perfusion past the initial occlusion, but no distal branch filling~~
~~☐ 2 - Perfusion with incomplete or slow distal branch filling~~
~~☐ 3 - Full perfusion with filling of all distal branches~~

~~3) Thrombolysis in Myocardial Infarction (TIMI) Perfusion Scale – Global Score (Scores listed and defined directly below):~~

~~**25 Global Score Table**~~

~~Score~~	~~Description (Score vessel-specific TIMI in each treatable vessel)~~
~~0~~	~~No perfusion~~
~~1~~	~~Perfusion past the initial occlusion, but no distal branch filling, in at least one treatable vessel~~
~~2~~	~~For MCA, all M1 and M2 segments at least TIMI 2; for ICA terminus, ICA, M1, and both M2 branches at least TIMI 2; for posterior circulation, both VA and BA at least TIMI 2~~
~~3~~	~~For MCA, all M1 and M2 segments at least TIMI 3; for ICA terminus, ICA, M1, and both M2 branches at least TIMI 3; for posterior circulation, both VA and BA at least TIMI 3~~

4) Qureshi Angiographic Occlusions Scale (Scores listed and defined directly below):

26 Occlusions Scale Table

Score	Description
0	No Occlusion
1 – MCA	MCA occlusion M3 segment

Score	Description
1 – ACA	ACA occlusion A2 or distal segments
1 – BA/VA	One BA/VA branch occlusion
2 – MCA	MCA occlusion M2 segment
2 – ACA	ACA occlusion A1 and A2 segments
2 – BA/VA	Two or more BA/VA branch occlusions
3A	MCA occlusion M1 segment with lentriculostriate arteries spared and/or leptomeningeal collaterals visualized
3B	MCA occlusion M1 segment with no sparing of lentriculostriate arteries nor leptomeningeal collaterals visualized
4A – ICA	ICA occlusion with collaterals filling MCA
4A – BA	BA occlusion with partial anterograde filling
4B – ICA	ICA occlusion with collaterals filling ACA
4B – BA	BA occlusion with partial retrograde filling
5 – ICA	ICA occlusion with no collaterals
5 – BA	BA occlusion with no filling either directly or via collaterals

5) Expanded Thrombolysis in Cerebral Infarction (eTICI) Perfusion Scale-Grade (Scores listed and defined directly below):

3 Perfusion Scale Cause and Symptomology Table

Score	Description
Grade 0	No ~~Perfusion. No antegrade flow beyond the point of occlusion.~~reperfusion or 0% filling of downstream territory.
Grade 1	~~Penetration With Minimal Perfusion. The contrast material passes beyond the area of obstruction but fails to opacify the entire cerebral bed distal to the obstruction for the duration of the angiographic run.~~Thrombus reduction without any reperfusion of distal arteries.
~~Grade 2~~	~~Partial Perfusion. The contrast material passes beyond the obstruction and opacifies the arterial bed distal to the obstruction. However, the rate of entry of contrast into the vessel distal to the obstruction and/or its rate of clearance from the distal bed are perceptibly slower than its entry into and/or clearance from comparable areas not perfused by the previously occluded vessel, eg, the opposite cerebral artery or the arterial bed proximal to the obstruction.~~
Grade 2a	Reperfusion in less than half or 1-49% of the territory.~~Only partial filling (<2/3) of the entire vascular territory is visualized.~~
Grade 2b50	~~Complete filling of all of the expected vascular territory is visualized, but the filling is slower than normal.~~50-66% reperfusion, exceeding the modified TICI (mTICI) 2B threshold but below the original TICI 2B cut-off point.
Grade 2b67	67-89% reperfusion, exceeding TICI but below TICI 2C.
Grade 2c	Equivalent to TICI 2C or 90-99% reperfusion.
Grade 3	Complete ~~Perfusion. Antegrade flow into the bed distal to the obstruction occurs as promptly as into the obstruction and clearance of contrast material from the involved bed is as rapid as from an uninvolved other bed of the same vessel or the opposite cerebral artery.~~or 100% reperfusion, tantamount to TICI 3.

6) Arterial Occlusion Lesion (AOL) Recanalization Scale for DSA; Modified Arterial Occlusion Lesion (mAOL) Recanalization Scale for CTA and MRA (Scores listed and defined directly below):

4 Recanalization Scale Table

Score	Description
0	No recanalization of the primary occlusive lesion
1	Incomplete or partial recanalization of the primary occlusive lesion with no distal flow
2	Incomplete or partial recanalization of the primary occlusive lesion with any distal flow
3	Complete recanalization of the primary occlusion with any distal flow

7) Intracranial collateral segment status:

5 Intracranial collateral segment status Table

Location	Side
ECA/OA - ICA	☐ Left ☐ Right ☐ Bilateral ☐ N/A – Not Present ~~status~~
ECA/Other - ICA	☐ Left ☐ Right ☐ Bilateral ☐ N/A – Not Present ~~status~~
AComA - A1 - MCA	☐ Left ☐ Right ☐ Bilateral ☐ N/A – Not Present ~~status~~
AComA – A2 – MCA pial	☐ Left ☐ Right ☐ Bilateral ☐ N/A – Not Present ~~status~~
PComA – ICA	☐ Left ☐ Right ☐ Bilateral ☐ N/A – Not Present ~~status~~
PCA – ACA pial	☐ Left ☐ Right ☐ Bilateral ☐ N/A – Not Present ~~status~~
PCA – MCA pial	☐ Left ☐ Right ☐ Bilateral ☐ N/A – Not Present ~~status~~
ICA to MCA/ACA Moyamoya	☐ Left ☐ Right ☐ Bilateral ☐ N/A – Not Present ~~status~~
Other:	☐ Left ☐ Right ☐ Bilateral ☐ N/A – Not Present ~~status~~

8) Collateral grade (Grades listed and defined directly below):

6a ASITN Collateral Grade Table

Score	Description
Grade 0	No collaterals visible to the ischemic site
Grade 1	Slow collaterals to the periphery of the ischemic site with persistence of some of the defect
Grade 2	Rapid collaterals to the periphery of ischemic site with persistence of some of the defect and to only a portion of the ischemic territory
Grade 3	Collaterals with slow but complete angiographic blood flow of the ischemic bed by the late venous phase
Grade 4	Complete and rapid collateral blood flow to the vascular bed in the entire ischemic territory by retrograde perfusion

6b Tan Collateral Score Table

Score	Description
0	Absence of vessels on CTA source images (CTA-SI)
1	Collateral supply filling ≤50% but >0% of the occluded MCA territory
2	Collateral supply filling >50% but <100% of the occluded MCA territory
3	100% collateral supply of the occluded MCA territory

9) Venous findings:
   a. Superior Sagittal Sinus findings:

7 Findings Table

Overall Assessment	☐ Normal ☐ Small Caliber/Congenital Hypoplasia ☐ Stenosis~~Impaired Flow~~ ☐ Occlusion ☐ Other
~~Presumed Pathogenesis~~	~~☐ Congenital Hypoplasia~~ ~~☐ Thrombosis~~ ~~☐ Stenosis~~
~~Level of Confidence~~	~~☐ High~~ ~~☐ Moderate~~ ~~☐ Low~~

10) Inferior Sagittal Sinus findings:

8 Findings Table

Overall Assessment	☐ Normal ☐ Small Caliber/Congenital Hypoplasia ☐ Stenosis~~Impaired Flow~~ ☐ Occlusion ☐ Other
~~Presumed Pathogenesis~~	~~☐ Congenital Hypoplasia~~ ~~☐ Thrombosis~~ ~~☐ Stenosis~~
~~Level of Confidence~~	~~☐ High~~ ~~☐ Moderate~~ ~~☐ Low~~

11) Straight Sinus findings:

9 Findings Table

Overall Assessment	☐ Normal ☐ Small Caliber/Congenital Hypoplasia ☐ Stenosis~~Impaired Flow~~ ☐ Occlusion ☐ Other
~~Presumed Pathogenesis~~	~~☐ Congenital Hypoplasia~~ ~~☐ Thrombosis~~ ~~☐ Stenosis~~
~~Level of Confidence~~	~~☐ High~~ ~~☐ Moderate~~ ~~☐ Low~~

12) Transverse Sinus findings:

10 Findings Table

Side	Right	Left
Overall Assessment	☐ Normal ☐ Small Caliber/Congenital Hypoplasia ☐ Stenosis ☐ Occlusion ☐ Other ~~☐ Impaired Flow~~	☐ Normal ☐ Small Caliber/Congenital Hypoplasia ☐ Stenosis ☐ Occlusion ☐ Other ~~☐ Impaired Flow~~
~~Presumed Pathogenesis~~	~~☐ Congenital Hypoplasia~~ ~~☐ Thrombosis~~ ~~☐ Stenosis~~	~~☐ Congenital Hypoplasia~~ ~~☐ Thrombosis~~ ~~☐ Stenosis~~
~~Level of Confidence~~	~~☐ High~~ ~~☐ Moderate~~ ~~☐ Low~~	~~☐ High~~ ~~☐ Moderate~~ ~~☐ Low~~

13) Sigmoid Sinus findings:

11 Findings Table

Side	Right	Left
Overall Assessment	☐ Normal ☐ Small Caliber/Congenital Hypoplasia ☐ Stenosis ☐ Occlusion ☐ Other ☐ ~~Impaired Flow~~	☐ Normal ☐ Small Caliber/Congenital Hypoplasia ☐ Stenosis ☐ Occlusion ☐ Other ☐ ~~Impaired Flow~~
~~Presumed Pathogenesis~~	☐ ~~Congenital Hypoplasia~~ ☐ ~~Thrombosis~~ ☐ ~~Stenosis~~	☐ ~~Congenital Hypoplasia~~ ☐ ~~Thrombosis~~ ☐ ~~Stenosis~~
~~Level of Confidence~~	☐ ~~High~~ ☐ ~~Moderate~~ ☐ ~~Low~~	☐ ~~High~~ ☐ ~~Moderate~~ ☐ ~~Low~~

14) Jugular Bulb findings:

12 Findings Table

Side	Right	Left
Overall Assessment	☐ Normal ☐ Small Caliber/Congenital Hypoplasia ☐ Stenosis ☐ Occlusion ☐ Other ☐ ~~Impaired Flow~~	☐ Normal ☐ Small Caliber/Congenital Hypoplasia ☐ Stenosis ☐ Occlusion ☐ Other ☐ ~~Impaired Flow~~
~~Presumed Pathogenesis~~	☐ ~~Congenital Hypoplasia~~ ☐ ~~Thrombosis~~ ☐ ~~Stenosis~~	☐ ~~Congenital Hypoplasia~~ ☐ ~~Thrombosis~~ ☐ ~~Stenosis~~
~~Level of Confidence~~	☐ ~~High~~ ☐ ~~Moderate~~ ☐ ~~Low~~	☐ ~~High~~ ☐ ~~Moderate~~ ☐ ~~Low~~

15) Cavernous Sinus findings:

13Findings Table

Side	Right	Left
Overall Assessment	☐ Normal ☐ Small Caliber/Congenital Hypoplasia ☐ Stenosis ☐ Occlusion ☐ Other ☐ ~~Impaired Flow~~	☐ Normal ☐ Small Caliber/Congenital Hypoplasia ☐ Stenosis ☐ Occlusion ☐ Other ☐ ~~Impaired Flow~~
~~Presumed Pathogenesis~~	☐ ~~Congenital Hypoplasia~~ ☐ ~~Thrombosis~~ ☐ ~~Stenosis~~	☐ ~~Congenital Hypoplasia~~ ☐ ~~Thrombosis~~ ☐ ~~Stenosis~~
~~Level of Confidence~~	☐ ~~High~~ ☐ ~~Moderate~~ ☐ ~~Low~~	☐ ~~High~~ ☐ ~~Moderate~~ ☐ ~~Low~~

16) Internal Cerebral Vein findings:

14: Findings Table

Side	Right	Left
Overall Assessment	☐ Normal ☐ Small Caliber/Congenital Hypoplasia ☐ Stenosis ☐ Occlusion ☐ Other ☐ ~~Impaired Flow~~	☐ Normal ☐ Small Caliber/Congenital Hypoplasia ☐ Stenosis ☐ Occlusion ☐ Other ☐ ~~Impaired Flow~~
~~Presumed Pathogenesis~~	☐ ~~Congenital Hypoplasia~~ ☐ ~~Thrombosis~~ ☐ ~~Stenosis~~	☐ ~~Congenital Hypoplasia~~ ☐ ~~Thrombosis~~ ☐ ~~Stenosis~~
~~Level of Confidence~~	☐ ~~High~~ ☐ ~~Moderate~~ ☐ ~~Low~~	☐ ~~High~~ ☐ ~~Moderate~~ ☐ ~~Low~~

17) a. Vein of Galen findings:

15a Findings Table

Overall Assessment	☐ Normal ☐ Small Caliber/Congenital Hypoplasia ☐ Stenosis~~Impaired Flow~~ ☐ Occlusion ☐ Other
~~Presumed Pathogenesis~~	☐ ~~Congenital Hypoplasia~~ ☐ ~~Thrombosis~~ ☐ ~~Stenosis~~
~~Level of Confidence~~	☐ ~~High~~ ☐ ~~Moderate~~ ☐ ~~Low~~

b. Frontal Cortical Vein findings:

15b Findings Table

Side	Right	Left
Overall Assessment	☐ Normal ☐ Small Caliber/Congenital Hypoplasia ☐ Stenosis ☐ Occlusion ☐ Other ☐ ~~Impaired Flow~~	☐ Normal ☐ Small Caliber/Congenital Hypoplasia ☐ Stenosis ☐ Occlusion ☐ Other ☐ ~~Impaired Flow~~
~~Presumed Pathogenesis~~	☐ ~~Congenital Hypoplasia~~ ☐ ~~Thrombosis~~ ☐ ~~Stenosis~~	☐ ~~Congenital Hypoplasia~~ ☐ ~~Thrombosis~~ ☐ ~~Stenosis~~
~~Level of Confidence~~	☐ ~~High~~ ☐ ~~Moderate~~ ☐ ~~Low~~	☐ ~~High~~ ☐ ~~Moderate~~ ☐ ~~Low~~

18) Parietal Cortical Vein findings:

16 Findings Table

Side	Right	Left
Overall Assessment	☐ Normal ☐ Small Caliber/Congenital Hypoplasia ☐ Stenosis ☐ Occlusion ☐ Other ☐ ~~Impaired Flow~~	☐ Normal ☐ Small Caliber/Congenital Hypoplasia ☐ Stenosis ☐ Occlusion ☐ Other ☐ ~~Impaired Flow~~
~~Presumed Pathogenesis~~	☐ ~~Congenital Hypoplasia~~ ☐ ~~Thrombosis~~ ☐ ~~Stenosis~~	☐ ~~Congenital Hypoplasia~~ ☐ ~~Thrombosis~~ ☐ ~~Stenosis~~
~~Level of Confidence~~	☐ ~~High~~ ☐ ~~Moderate~~ ☐ ~~Low~~	☐ ~~High~~ ☐ ~~Moderate~~ ☐ ~~Low~~

19) Temporal Cortical Vein findings:

17 Findings Table

Side	Right	Left
Overall Assessment	☐ Normal ☐ Small Caliber/Congenital Hypoplasia ☐ Stenosis ☐ Occlusion ☐ Other ☐ ~~Impaired Flow~~	☐ Normal ☐ Small Caliber/Congenital Hypoplasia ☐ Stenosis ☐ Occlusion ☐ Other ☐ ~~Impaired Flow~~
~~Presumed Pathogenesis~~	☐ ~~Congenital Hypoplasia~~ ☐ ~~Thrombosis~~ ☐ ~~Stenosis~~	☐ ~~Congenital Hypoplasia~~ ☐ ~~Thrombosis~~ ☐ ~~Stenosis~~
~~Level of Confidence~~	☐ ~~High~~ ☐ ~~Moderate~~ ☐ ~~Low~~	☐ ~~High~~ ☐ ~~Moderate~~ ☐ ~~Low~~

20) Occipital Cortical Vein findings:

18 Findings Table

Side	Right	Left
Overall Assessment	☐ Normal ☐ Small Caliber/Congenital Hypoplasia ☐ Stenosis ☐ Occlusion ☐ Other ☐ ~~Impaired Flow~~	☐ Normal ☐ Small Caliber/Congenital Hypoplasia ☐ Stenosis ☐ Occlusion ☐ Other ☐ ~~Impaired Flow~~
~~Presumed Pathogenesis~~	☐ ~~Congenital Hypoplasia~~ ☐ ~~Thrombosis~~ ☐ ~~Stenosis~~	☐ ~~Congenital Hypoplasia~~ ☐ ~~Thrombosis~~ ☐ ~~Stenosis~~
~~Level of Confidence~~	☐ ~~High~~ ☐ ~~Moderate~~ ☐ ~~Low~~	☐ ~~High~~ ☐ ~~Moderate~~ ☐ ~~Low~~

~~21) Collateral status:~~

~~27 Collateral status Table~~

~~Location~~	~~Side~~
~~ECA/OA - ICA~~	☐ ~~Left~~ ☐ ~~Right~~ ☐ ~~Bilateral~~ ☐ ~~N/A – No status~~
~~ECA/Other – ICA~~	☐ ~~Left~~ ☐ ~~Right~~ ☐ ~~Bilateral~~ ☐ ~~N/A – No status~~
~~AComA - A1 - MCA~~	☐ ~~Left~~ ☐ ~~Right~~ ☐ ~~Bilateral~~ ☐ ~~N/A – No status~~
~~AComA – A2 – MCA pial~~	☐ ~~Left~~ ☐ ~~Right~~ ☐ ~~Bilateral~~ ☐ ~~N/A – No status~~
~~PComA – ICA~~	☐ ~~Left~~ ☐ ~~Right~~ ☐ ~~Bilateral~~ ☐ ~~N/A – No status~~
~~PCA – ACA pial~~	☐ ~~Left~~ ☐ ~~Right~~ ☐ ~~Bilateral~~ ☐ ~~N/A – No status~~
~~PCA – MCA pial~~	☐ ~~Left~~ ☐ ~~Right~~ ☐ ~~Bilateral~~ ☐ ~~N/A – No status~~
~~ICA to MCA/ACA Moyamoya~~	☐ ~~Left~~ ☐ ~~Right~~ ☐ ~~Bilateral~~ ☐ ~~N/A – No status~~
~~Other:~~	☐ ~~Left~~ ☐ ~~Right~~ ☐ ~~Bilateral~~ ☐ ~~N/A – No status~~

~~22) Collateral grade (Grades listed and defined directly below):~~

~~28 Collateral Grade Table~~

~~Score~~	~~Description~~
~~Grade 0~~	~~No collaterals visible to the ischemic site~~
~~Grade 1~~	~~Slow collaterals to the periphery of the ischemic site with persistence of some of the defect~~
~~Grade 2~~	~~Rapid collaterals to the periphery of ischemic site with persistence of some of the defect and to only a portion of the ischemic territory~~
~~Grade 3~~	~~Collaterals with slow but complete angiographic blood flow of the ischemic bed by the late venous phase~~
~~Grade 4~~	~~Complete and rapid collateral blood flow to the vascular bed in the entire ischemic territory by retrograde perfusion~~

ANEURYSM DETAILS

1) Shape/pathology of aneurysm:

- ☐ Saccular
- ☐ Fusiform
- ☐ Dissecting

2) **Anatomic location:

- ☐ C1 cervical
- ☐ C2 petrous
- ☐ C3 lacerum
- ☐ C4 cavernous
- ☐ C5 clinoidal
- ☐ C6 - ophthalmic to PCOM
- ☐ C6 - PCOM to terminus
- ☐ A1
- ☐ ACOM
- ☐ A2
- ☐ M1 proximal to striate
- ☐ M1 distal to striate
- ☐ M2
- ☐ M2 single
- ☐ M2 multiple
- ☐ M3
- ☐ M3 single
- ☐ M3 multiple
- ☐ M4
- ☐ M4 single
- ☐ M4 multiple
- ☐ Vertebral origin
- ☐ Vertebral-cervical
- ☐ Vertebral-intracranial proximal to PICA
- ☐ Vertebral-distal to PICA
- ☐ Basilar-distal to AICA
- ☐ Basilar-mid
- ☐ Basilar-proximal to AICA
- ☐ PCOM
- ☐ P1
- ☐ P2
- ☐ P3
- ☐ SCA
- ☐ AICA
- ☐ PICA

3) **Location of aneurysm:

- ☐ Cavernous
- ☐ Persistent trigeminal
- ☐ Medial paraclinoid
- ☐ Lateral paraclinoid

☐ Ophthalmic

☐ Superior hypophyseal

☐ Posterior communicating

☐ Anterior choroidal

☐ Internal carotid artery bifurcation

☐ Middle cerebral artery bifurcation

☐ Anterior communicating

☐ Pericallosal

☐ Posterior inferior cerebellar artery

☐ Superior cerebellar

☐ Basilar apex

☐ Other

4) **Dome size of aneurysm (mm):
5) **Neck size of aneurysm (mm):
6) Aneurysm irregularity:
☐ Yes

☐ No

☐ Unknown

7) **Largest height/largest neck diameter for each aneurysm:
8) Presence of mural thrombus or partial thrombosis in aneurysm:
☐ Yes

☐ No

☐ Unknown

9) Presence of 3D reconstruction of aneurysm:
☐ Yes

☐ No

☐ Unknown

Endovascular Aneurysm Treatment

1) Wall opposition for stents or flow diverters:
☐ Good

☐ Poor

☐ Unknown

2) **Occlusion percentage of aneurysm:
3) **Raymond-Roy Occlusion Classification:
☐ Complete occlusion

☐ Dog ear

☐ Residual neck

☐ Residual aneurysm

4) Occlusion of parent or branch vessel related to aneurysm:
☐ Yes

☐ No

☐ Unknown

***CFD: Volumetric

1) Mean kinetic energy measurement of aneurysm:
2) Mean velocity measurement of aneurysm (cm/sec):
3) Mean aneurysm shear rate:
4) Mean aneurysm vorticity:
5) Mean viscous dissipation:
6) Vortex coreline length (cm):

CFD: Surface Factors

7) Mean wall shear stress of aneurysm (dyne/cm^2):
8) Maximum wall shear stress (dyne/cm^2):
9) Minimum wall shear stress (dyne/cm^2):
10) ***Shear concentration index:
11) ***Percentage of aneurysm under low WSS:
12) ***Mean oscillatory shear stress

CFD: Hemodynamic Factors

13) ***Mean inflow rate of aneurysm (ml/sec):
14) ***Inflow concentration index:

Additional Supplemental Elements

1) Vascular dissection extent type (Choose one):

☐ Luminal narrowing greater than 50% (including "string sign")

☐ Vessel occlusion

☐ Luminal narrowing less than 50%

2) Vascular dissection findings type (Choose one):

☐ Watershed or embolic infarction in the territory of the dissected vessel with SAH

☐ Watershed or embolic infarction in the territory of the dissected vessel without SAH

☐ Adjacent skull fracture (e.g. carotid canal)

3) Traumatic aneurysm (Choose one):

☐ Present

☐ Absent

☐ Indeterminate

4) Traumatic aneurysm anatomic site (Choose all that apply):

Carotid	☐ R	☐ L
Vertebral	☐ R	☐ L
ACA	☐ R	☐ L
MCA	☐ R	☐ L
PCA	☐ R	☐ L
Basilar	☐	
Other (Describe):	☐ R	☐ L

5) Traumatic aneurysm volume measurement:

mm^3

6) Traumatic aneurysm findings type (Choose one):

☐ Intraluminal thrombus

☐ Cavernous (intradural)

☐ Skull fracture, with penetrating injury

☐ Skull fracture, without penetrating injury

7) Venous sinus injury (Choose one):

☐ Present

☐ Absent

☐ Indeterminate

8) Venous sinus injury morphology type (Choose all that apply):

☐ Compression

☐ Occlusion

☐ Laceration

9) Venous sinus injury anatomic site (Choose all that apply):

Sagittal sinus	☐ Posterior (occipital)
	☐ Anterior (frontoparietal)
Transverse sinus	☐ R ☐ L
Sigmoid sinus	☐ R ☐ L

General Instructions

This CRF contains data that would be collected when an imaging study is performed using angiography to examine the blood vessels of the body. There are separate sections to record arterial findings and venous findings.

Important note: A subset of the data elements included on this CRF Module is considered Core (i.e., strongly recommended for stroke clinical studies to collect if imaging studies are performed). The remaining data elements (i.e., non Core) are supplemental and should only be collected if the research team considers them appropriate for their study.

*Element is classified as Core if protocol includes imaging

** Element is classified as Supplemental – Highly Recommended

***Element is classified as Exploratory

The remaining data elements are Supplemental and should only be collected if the research team considers them appropriate for their study.

Specific Instructions

Please see the Data Dictionary for definitions for each of the data elements included in this CRF Module.

PATIENT INFORMATION

1. *Study ID number:
2. *Date and time of study (M M/D D/Y Y Y Y):
   (HH:MM, 24 hr clock):
3. NIH Stroke Scale (NIHSS) at time of study (0-42):[7]
4. Scan purpose (Select all that apply):
   - ☐ ~~Diagnostic~~Initial
   - ☐ ~~Post-treatment~~
   - ☐ Monitoring

TECHNICAL INFORMATION

1. Ultrasound Type:
   - ☐ Transcranial Color-coded Real-time Sonography (TCCS)
   - ☐ Transcranial Doppler (TCD)
2. Probe:
   a. Type:
   b. Frequency (Hz):
3. Patient type:
   a. ☐ Asymptomatic
   b. ☐ Acute Stroke
      If Acute Stroke, indicate study type:
      - ☐ Initial
      - ☐ Follow-up 1
      - ☐ Follow-up 2
   c. ☐ Chronic ~~Stroke~~

      i. ☐ Stroke:
         - ☐ Hemisphere
         - ☐ Eye
         - ☐ Vertebrobasilar

      ii. ☐ TIA:
         - ☐ Hemisphere
         - ☐ Eye
         - ☐ Vertebrobasilar

      iii. Laterality:
         - ☐ Left
         - ☐ Right

   d. ☐ Brain Edema

[7] NIHSS is also included on other Stroke CDE CRF Modules. This item should be pre-populated if initially collected elsewhere so as to avoid redundant data points.

e. ☐ Brain Death
f. ☐ Sickle Cell
g. ☐ Arteriovenous Malformation
h. ☐ Monitoring
i. ☐ Right Shunt
j. ☐ Left Shunt

k. ☐ Vasospasm

4. Interpretation site:
   a. ☐ Onsite
   b. ☐ Offsite

   If Offsite, indicate type:
   ☐Video
   ☐Print
   ☐Digital

5. Contrast Agent:
   ☐Yes

   Type:
   ☐Bolus
   ☐Infusion
   ☐Other, specify:

   ☐No

~~6. Read type (Select all that apply):~~
~~☐Local read~~
~~☐Local report~~
~~☐Central read~~

~~7. Reader blinded to clinical data:~~
~~☐Yes~~
~~☐No~~

~~8. Study technically satisfactory:~~
~~☐Yes~~
~~☐No~~

9. Insonation plane:
   ☐Free
   ☐Coronal
   ☐Axial mesencephalic

10. Insonation window:
   ☐Orbital
      ☐ Excellent
      ☐ Fair
      ☐ Poor
   ☐Temporal
      ☐ Excellent
      ☐ Fair

☐ Poor
☐Posterior
☐ Excellent
☐ Fair
☐ Poor

*VESSELS

(All elements in this section are considered Core Stroke CDEs for TCCS)

1. M1

29 Vessels M1 Table

Side	Right	Left
B-mode	☐Normal ☐Stenosis ☐Occlusion	☐Normal ☐Stenosis ☐Occlusion
Color flow	☐Yes ☐No	☐Yes ☐No
Spectrum	Depth (mm): Angle correction: ☐Yes ☐No Peak velocity (cm/sec): Mean velocity (cm/sec): Direction to Probe: ☐Towards ☐Away from Asymmetry index: End diastolic ratio: COGIF score: ☐No flow ☐Low flow/No diastolic flow ☐Low flow/diastolic flow ☐Established perfusion COGIF Follow-up: ☐Yes ☐No If yes, Date (M M/D D/Y Y Y Y): (HH:MM, 24 hr clock):	Depth (mm): Angle correction: ☐Yes ☐No Peak velocity (cm/sec): Mean velocity (cm/sec): Direction to Probe: ☐Towards ☐Away from Asymmetry index: End diastolic ratio: COGIF score: ☐No flow ☐Low flow/No diastolic flow ☐Low flow/diastolic flow ☐Established perfusion COGIF Follow-up: ☐Yes ☐No If yes, Date (M M/D D/Y Y Y Y): (HH:MM, 24 hr clock):
Symptomatic?	☐Yes ☐No	☐Yes ☐No
Depth	(mm):	(mm):
Findings: (select all that apply)	☐ No Signal ☐ Systolic Spike ☐ Reversed Diastolic Flow ☐ Reduced upstroke/ Pulsatility Index	☐ No Signal ☐ Systolic Spike ☐ Reversed Diastolic Flow ☐ Reduced upstroke/ Pulsatility Index
Flow Direction:	☐ Towards ☐ Away from	☐ Towards ☐ Away from

2. Insular M2

30 Vessels Insular M2 Table

Side	Right	Left
B-mode	☐Normal	☐Normal

Side	Right	Left
	☐Stenosis ☐Occlusion	☐Stenosis ☐Occlusion
Color flow	☐Yes ☐No	☐Yes ☐No
Spectrum	Depth (mm): Angle correction: ☐Yes ☐No Peak velocity (cm/sec): Mean velocity (cm/sec): Direction to Probe: ☐Towards ☐Away from Asymmetry index: End diastolic ratio: COGIF score: ☐No flow ☐Low flow/No diastolic flow ☐Low flow/diastolic flow ☐Established perfusion COGIF Follow-up: ☐Yes ☐No If yes, Date (M M/D D/Y Y Y Y): (HH:MM, 24 hr clock):	Depth (mm): Angle correction: ☐Yes ☐No Peak velocity (cm/sec): Mean velocity (cm/sec): Direction to Probe: ☐Towards ☐Away from Asymmetry index: End diastolic ratio: COGIF score: ☐No flow ☐Low flow/No diastolic flow ☐Low flow/diastolic flow ☐Established perfusion COGIF Follow-up: ☐Yes ☐No If yes, Date (M M/D D/Y Y Y Y): (HH:MM, 24 hr clock):
Symptomatic?	☐Yes ☐No	☐Yes ☐No
Depth	(mm):	(mm):
Findings: (select all that apply)	☐ No Signal ☐ Systolic Spike ☐ Reversed Diastolic Flow ☐ Reduced upstroke/ Pulsatility Index	☐ No Signal ☐ Systolic Spike ☐ Reversed Diastolic Flow ☐ Reduced upstroke/ Pulsatility Index
Flow Direction:	☐ Towards ☐ Away from	☐ Towards ☐ Away from

3. A1

31 Vessels A1 Table

Side	Right	Left
B-mode	☐Normal ☐Stenosis ☐Occlusion	☐Normal ☐Stenosis ☐Occlusion
Color flow	☐Yes ☐No	☐Yes ☐No
Spectrum	Depth (mm): Angle correction: ☐Yes ☐No Peak velocity (cm/sec): Mean velocity (cm/sec): Direction to Probe: ☐Towards ☐Away from Asymmetry index: End diastolic ratio:	Depth (mm): Angle correction: ☐Yes ☐No Peak velocity (cm/sec): Mean velocity (cm/sec): Direction to Probe: ☐Towards ☐Away from Asymmetry index: End diastolic ratio:

Side	Right	Left
	COGIF score: ☐No flow ☐Low flow/No diastolic flow ☐Low flow/diastolic flow ☐Established perfusion COGIF Follow-up: ☐Yes ☐No If yes, Date (M M/D D/Y Y Y Y): (HH:MM, 24 hr clock):	COGIF score: ☐No flow ☐Low flow/No diastolic flow ☐Low flow/diastolic flow ☐Established perfusion COGIF Follow-up: ☐Yes ☐No If yes, Date (M M/D D/Y Y Y Y): (HH:MM, 24 hr clock):
Symptomatic?	☐Yes ☐No	☐Yes ☐No
Depth	(mm):	(mm):
Findings: (select all that apply)	☐ No Signal ☐ Systolic Spike ☐ Reversed Diastolic Flow ☐ Reduced upstroke/ Pulsatility Index	☐ No Signal ☐ Systolic Spike ☐ Reversed Diastolic Flow ☐ Reduced upstroke/ Pulsatility Index
Flow Direction:	☐ Towards ☐ Away from	☐ Towards ☐ Away from

4. Internal Carotid Artery (ICA)

32: Vessels ICA Table

Side	Right	Left
B-mode	☐Normal ☐Stenosis ☐Occlusion	☐Normal ☐Stenosis ☐Occlusion
Color flow	☐Yes ☐No	☐Yes ☐No
Spectrum	Depth (mm): Angle correction: ☐Yes ☐No Peak velocity (cm/sec): Mean velocity (cm/sec): Direction to Probe: ☐Towards ☐Away from Asymmetry index: End diastolic ratio: COGIF score: ☐No flow ☐Low flow/No diastolic flow ☐Low flow/diastolic flow ☐Established perfusion COGIF Follow-up: ☐Yes ☐No If yes, Date (M M/D D/Y Y Y Y): (HH:MM, 24 hr clock):	Depth (mm): Angle correction: ☐Yes ☐No Peak velocity (cm/sec): Mean velocity (cm/sec): Direction to Probe: ☐Towards ☐Away from Asymmetry index: End diastolic ratio: COGIF score: ☐No flow ☐Low flow/No diastolic flow ☐Low flow/diastolic flow ☐Established perfusion COGIF Follow-up: ☐Yes ☐No If yes, Date (M M/D D/Y Y Y Y): (HH:MM, 24 hr clock):
Symptomatic?	☐Yes ☐No	☐Yes ☐No
Depth	(mm):	(mm):
Findings: (select all that apply)	☐ No Signal ☐ Systolic Spike	☐ No Signal ☐ Systolic Spike

Side	Right	Left
	☐ Reversed Diastolic Flow ☐ Reduced upstroke/ Pulsatility Index	☐ Reversed Diastolic Flow ☐ Reduced upstroke/ Pulsatility Index
Flow Direction:	☐ Towards ☐ Away from	☐ Towards ☐ Away from

5. P1

33: Vessels P1 Table

Side	Right	Left
B-mode	☐Normal ☐Stenosis ☐Occlusion	☐Normal ☐Stenosis ☐Occlusion
Color flow	☐Yes ☐No	☐Yes ☐No
Spectrum	Depth (mm): Angle correction: ☐Yes ☐No Peak velocity (cm/sec): Mean velocity (cm/sec): Direction to Probe: ☐Towards ☐Away from Asymmetry index: End diastolic ratio: COGIF score: ☐No flow ☐Low flow/No diastolic flow ☐Low flow/diastolic flow ☐Established perfusion COGIF Follow-up: ☐Yes ☐No If yes, Date (M M/D D/Y Y Y Y): (HH:MM, 24 hr clock):	Depth (mm): Angle correction: ☐Yes ☐No Peak velocity (cm/sec): Mean velocity (cm/sec): Direction to Probe: ☐Towards ☐Away from Asymmetry index: End diastolic ratio: COGIF score: ☐No flow ☐Low flow/No diastolic flow ☐Low flow/diastolic flow ☐Established perfusion COGIF Follow-up: ☐Yes ☐No If yes, Date (M M/D D/Y Y Y Y): (HH:MM, 24 hr clock):
Symptomatic?	☐Yes ☐No	☐Yes ☐No
Depth	(mm):	(mm):
Findings: (select all that apply)	☐ No Signal ☐ Systolic Spike ☐ Reversed Diastolic Flow ☐ Reduced upstroke/ Pulsatility Index	☐ No Signal ☐ Systolic Spike ☐ Reversed Diastolic Flow ☐ Reduced upstroke/ Pulsatility Index
Flow Direction:	☐ Towards ☐ Away from	☐ Towards ☐ Away from

6. P2

34: Vessels P2 Table

Side	Right	Left
B-mode	☐Normal ☐Stenosis ☐Occlusion	☐Normal ☐Stenosis ☐Occlusion
Color flow	☐Yes ☐No	☐Yes ☐No
Spectrum	Depth (mm): Angle correction:	Depth (mm): Angle correction:

Side	Right	Left
	☐Yes ☐No Peak velocity (cm/sec): Mean velocity (cm/sec): Direction to Probe: ☐Towards ☐Away from Asymmetry index: End diastolic ratio: COGIF score: ☐No flow ☐Low flow/No diastolic flow ☐Low flow/diastolic flow ☐Established perfusion COGIF Follow-up: ☐Yes ☐No If yes, Date (M M/D D/Y Y Y Y): (HH:MM, 24 hr clock):	☐Yes ☐No Peak velocity (cm/sec): Mean velocity (cm/sec): Direction to Probe: ☐Towards ☐Away from Asymmetry index: End diastolic ratio: COGIF score: ☐No flow ☐Low flow/No diastolic flow ☐Low flow/diastolic flow ☐Established perfusion COGIF Follow-up: ☐Yes ☐No If yes, Date (M M/D D/Y Y Y Y): (HH:MM, 24 hr clock):
Symptomatic?	☐Yes ☐No	☐Yes ☐No
Depth	(mm):	(mm):
Findings: (select all that apply)	☐ No Signal ☐ Systolic Spike ☐ Reversed Diastolic Flow ☐ Reduced upstroke/ Pulsatility Index	☐ No Signal ☐ Systolic Spike ☐ Reversed Diastolic Flow ☐ Reduced upstroke/ Pulsatility Index
Flow Direction:	☐ Towards ☐ Away from	☐ Towards ☐ Away from

7. Vertebral

7: Vertebral Vessels Table

Side	Right	Left
B-mode	☐Normal ☐Stenosis ☐Occlusion	☐Normal ☐Stenosis ☐Occlusion
Color flow	☐Yes ☐No	☐Yes ☐No
Spectrum	Depth (mm): Angle correction: ☐Yes ☐No Peak velocity (cm/sec): Mean velocity (cm/sec): Direction to Probe: ☐Towards ☐Away from Asymmetry index: End diastolic ratio: COGIF score: ☐No flow ☐Low flow/No diastolic flow ☐Low flow/diastolic flow ☐Established perfusion COGIF Follow-up:	Depth (mm): Angle correction: ☐Yes ☐No Peak velocity (cm/sec): Mean velocity (cm/sec): Direction to Probe: ☐Towards ☐Away from Asymmetry index: End diastolic ratio: COGIF score: ☐No flow ☐Low flow/No diastolic flow ☐Low flow/diastolic flow ☐Established perfusion COGIF Follow-up:

Side	Right	Left
	☐Yes ☐No If yes, Date (M M/D D/Y Y Y Y): (HH:MM, 24 hr clock):	☐Yes ☐No If yes, Date (M M/D D/Y Y Y Y): (HH:MM, 24 hr clock):
Symptomatic?	☐Yes ☐No	☐Yes ☐No
Depth	(mm):	(mm):
Findings: (select all that apply)	☐ No Signal ☐ Systolic Spike ☐ Reversed Diastolic Flow ☐ Reduced upstroke/ Pulsatility Index	☐ No Signal ☐ Systolic Spike ☐ Reversed Diastolic Flow ☐ Reduced upstroke/ Pulsatility Index
Flow Direction:	☐ Towards ☐ Away from	☐ Towards ☐ Away from

8. Basilar

8: Basilar Vessels Table

Side	Right	Left
B-mode	☐Normal ☐Stenosis ☐Occlusion	☐Normal ☐Stenosis ☐Occlusion
Color flow	☐Yes ☐No	☐Yes ☐No
Spectrum	Depth (mm): Angle correction: ☐Yes ☐No Peak velocity (cm/sec): Mean velocity (cm/sec): Direction to Probe: ☐Towards ☐Away from Asymmetry index: End diastolic ratio: COGIF score: ☐No flow ☐Low flow/No diastolic flow ☐Low flow/diastolic flow ☐Established perfusion COGIF Follow-up: ☐Yes ☐No If yes, Date (M M/D D/Y Y Y Y): (HH:MM, 24 hr clock):	Depth (mm): Angle correction: ☐Yes ☐No Peak velocity (cm/sec): Mean velocity (cm/sec): Direction to Probe: ☐Towards ☐Away from Asymmetry index: End diastolic ratio: COGIF score: ☐No flow ☐Low flow/No diastolic flow ☐Low flow/diastolic flow ☐Established perfusion COGIF Follow-up: ☐Yes ☐No If yes, Date (M M/D D/Y Y Y Y): (HH:MM, 24 hr clock):
Symptomatic?	☐Yes ☐No	☐Yes ☐No
Depth	(mm):	(mm):
Findings: (select all that apply)	☐ No Signal ☐ Systolic Spike ☐ Reversed Diastolic Flow ☐ Reduced upstroke/ Pulsatility Index	☐ No Signal ☐ Systolic Spike ☐ Reversed Diastolic Flow ☐ Reduced upstroke/ Pulsatility Index
Flow Direction:	☐ Towards ☐ Away from	☐ Towards ☐ Away from

9. EC ICA

9: Vessels EC ICA Table

Side	Right	Left
B-mode	☐Normal ☐Stenosis ☐Occlusion	☐Normal ☐Stenosis ☐Occlusion

POWER M MODE

1. Left MCA:

☐ Absent
☐ High Resistance
☐ Low Resistance

2. Right MCA:

☐ Absent
☐ High Resistance
☐ Low Resistance

~~MICROEMBOLIC SIGNALS~~HIGH INTENSITY TRANSIENT SIGNAL HITS

~~1) Unidirectional?~~
~~☐Yes~~
~~☐No~~

1. Duration time (msec):
2. Intensity (dB):

~~3. Settings:~~

~~1. Leading cols (mm):~~
~~2. Trailing cols (mm):~~
~~3. Threshold (mm):~~
~~4. Rejection (mm):~~

4. A1:

Right	Left
☐Yes ☐No	☐Yes ☐No
Number:	Number:
Start Time: (hh:mm, 24 hr clock)	Start Time: (hh:mm, 24 hr clock)
End Time: (hh:mm, 24 hr clock)	End Time: (hh:mm, 24 hr clock)

5. Siphon:

Right	Left
☐Yes ☐No	☐Yes ☐No
Number:	Number:
Start Time: (hh:mm, 24 hr clock)	Start Time: (hh:mm, 24 hr clock)
End Time: (hh:mm, 24 hr clock)	End Time: (hh:mm, 24 hr clock)

6. P1:

Right	Left
☐Yes ☐No	☐Yes ☐No
Number:	Number:
Start Time: (hh:mm, 24 hr clock)	Start Time: (hh:mm, 24 hr clock)
End Time: (hh:mm, 24 hr clock)	End Time: (hh:mm, 24 hr clock)

7. M1:

Right	Left
☐Yes ☐No	☐Yes ☐No
Number:	Number:
Start Time: (hh:mm, 24 hr clock)	Start Time: (hh:mm, 24 hr clock)
End Time: (hh:mm, 24 hr clock)	End Time: (hh:mm, 24 hr clock)

8. Ophthalmic:

Right	Left
☐Yes ☐No	☐Yes ☐No
Number:	Number:
Start Time: (hh:mm, 24 hr clock)	Start Time: (hh:mm, 24 hr clock)
End Time: (hh:mm, 24 hr clock)	End Time: (hh:mm, 24 hr clock)

9. Vert:

Right	Left
☐Yes ☐No	☐Yes ☐No
Number:	Number:
Start Time: (hh:mm, 24 hr clock)	Start Time: (hh:mm, 24 hr clock)
End Time: (hh:mm, 24 hr clock)	End Time: (hh:mm, 24 hr clock)

10. Basilar:

☐Yes ☐No
Number:
Start Time: (hh:mm, 24 hr clock)
End Time: (hh:mm, 24 hr clock)

VASOMOTOR RESPONSE (VMR)

1. Vessel(s):
   ☐MCA

☐Other, specify:

2. VMR:
   ☐Normal (Skip to Diagnosis)
   ☐Abnormal
3. Breath-holding index (BHI):

DIAGNOSIS

1. Extracranial stenosis:
   ☐Yes (Select all that apply)
      a. ☐Collateral:
         ☐OA
         ☐ACA
         ☐VA
      b. ☐Reduced upstroke
      c. ☐Reduced Pulsatility Index (PI)
      d. ☐VMR
      e. ☐Reduced velocity

   ☐No
2. Intracranial stenosis:
   ☐Yes
      a. Vessel(s):
         ☐MCA
         ☐ICA
         ☐VA
         ☐Basilar
         ☐Other, specify:
      b. % Stenosis:
      c. Peak Systolic Velocity (PSV) criterion:
      d. Mean velocity criterion:
      e. Other:

   ☐No
3. Vasospasm:
   ☐Yes
      a. Severity:
         ☐Mild
         ☐Moderate
         ☐Severe
      b. Vessel(s):
         ☐MCA
         ☐ICA
         ☐VA
         ☐Basilar
      c. Criterion:
      d. Lindegaard ratio:
      e. Posterior ratio:

f. Intracranial pressure (ICP):
g. Resistive Index (RI):
h. Partial pressure of carbon dioxide (PCO2):
i. Hemoglobin:

☐No

4. Brain Death:
☐Yes (Select all that apply)
☐Reversed diastolic flow
☐Systolic spike
☐No signals

☐No

5. Sickle Cell (indication for study):
☐Normal

☐Conditional

a. Vessel(s):
☐MCA
☐Other, specify
b. Velocity:

☐Abnormal

a. Vessel(s):
☐MCA
☐Other, specify
b. Velocity:

General Instructions

This CRF contains data that would be collected when a transcranial vessel imaging study is performed to examine brain vessels and evaluate cerebral hemodynamics.

Important note: A subset of the data elements included on this CRF Module is considered Core (i.e., strongly recommended for stroke clinical studies to collect if imaging studies are performed). The remaining data elements (i.e., non Core) are supplemental and should only be collected if the research team considers them appropriate for their study.

*Element is classified as Core if protocol includes imaging

** Element is classified as Supplemental – Highly Recommended

***Element is classified as Exploratory

The remaining data elements are Supplemental and should only be collected if the research team considers them appropriate for their study.

Specific Instructions

Please see the Data Dictionary for definitions for each of the data elements included in this CRF Module.